

AEDV 2023 Highlights

Con el patrocinio de:



32º EDICIÓN • 32º EDICIÓN • 32º EDICIÓN • 32º EDICIÓN • 32º EDICIÓN • 32º EDICIÓN • 32º EDICIÓN • 32º EDICIÓN • 32º EDICIÓN • 32º EDICIÓN

BER LIN

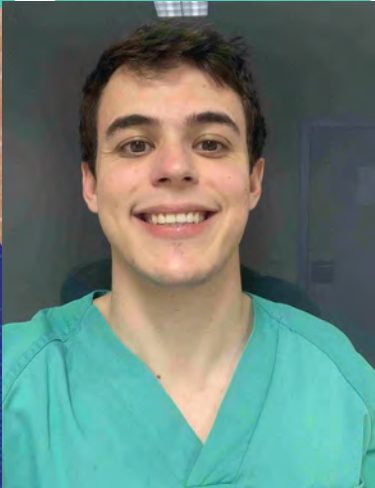11-14 OCTUBRE

Iniciativa científica de:



ACADEMIA ESPAÑOLA
DE DERMATOLOGÍA
Y VENEREOLOGÍA

AEDV2023 Highlights



Dermatología Pediátrica Parte I

Miguel Mansilla Polo

Hospital Universitario y Politécnico La Fe

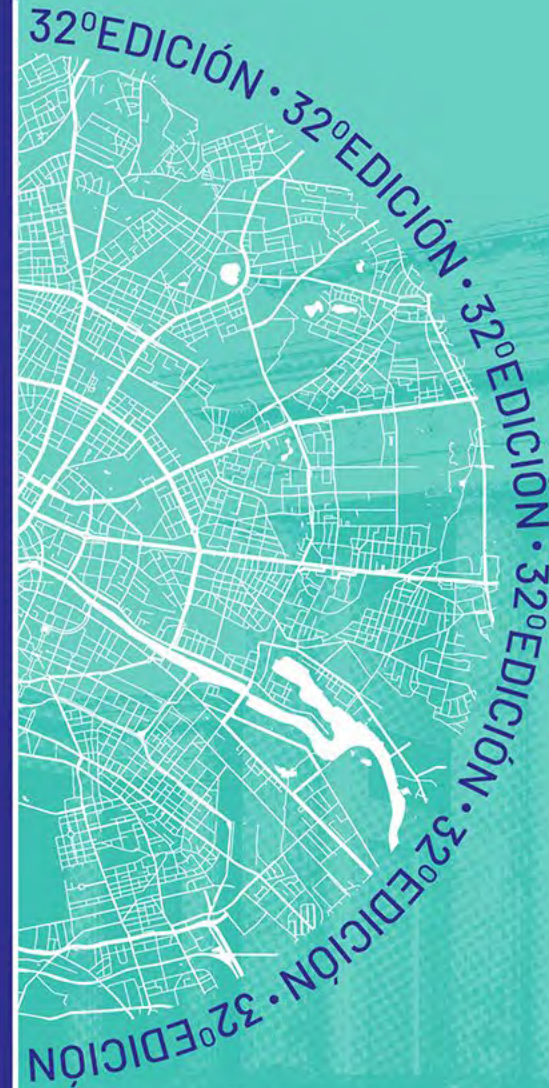


@mig_yec

Conflicto de intereses



UCB ha financiado esta ponencia



**BER
LIN**

11-14 OCTUBRE

Biologics in children

Focus on psoriasis

Tiago Torres, MD, PhD

*Department of Dermatology - Centro Hospitalar Universitário de Santo António
Unit for Multidisciplinary Research in Biomedicine – ICBAS/University of Porto*

Why to use highly effective drugs in pediatric psoriasis?

- Early and appropriate treatment of psoriasis is critical in the paediatric population
 - Children with psoriasis are likely to experience:
 - Social discrimination and stigmatization
 - Impairment in emotional, social and school functioning
 - Higher risk of depression and anxiety and to believe that psoriasis had caused their depression
 - Undertreatment of moderate-to-severe psoriasis: low use of systemic therapy, particularly biologics
- Psoriasis at a young age is likely to negatively influence children's social-emotional and personality development and future, resulting in an inability to achieve 'full-life potential' (also termed cumulative life course impairment)

Psoriasis' cumulative life course impairment

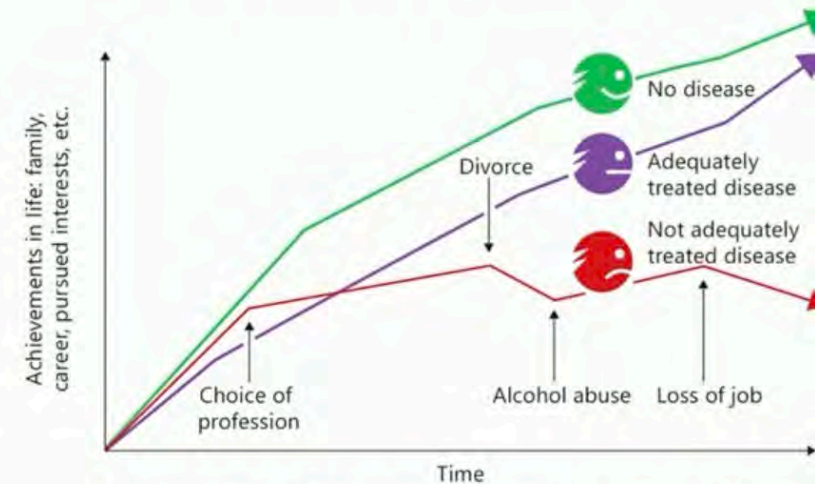
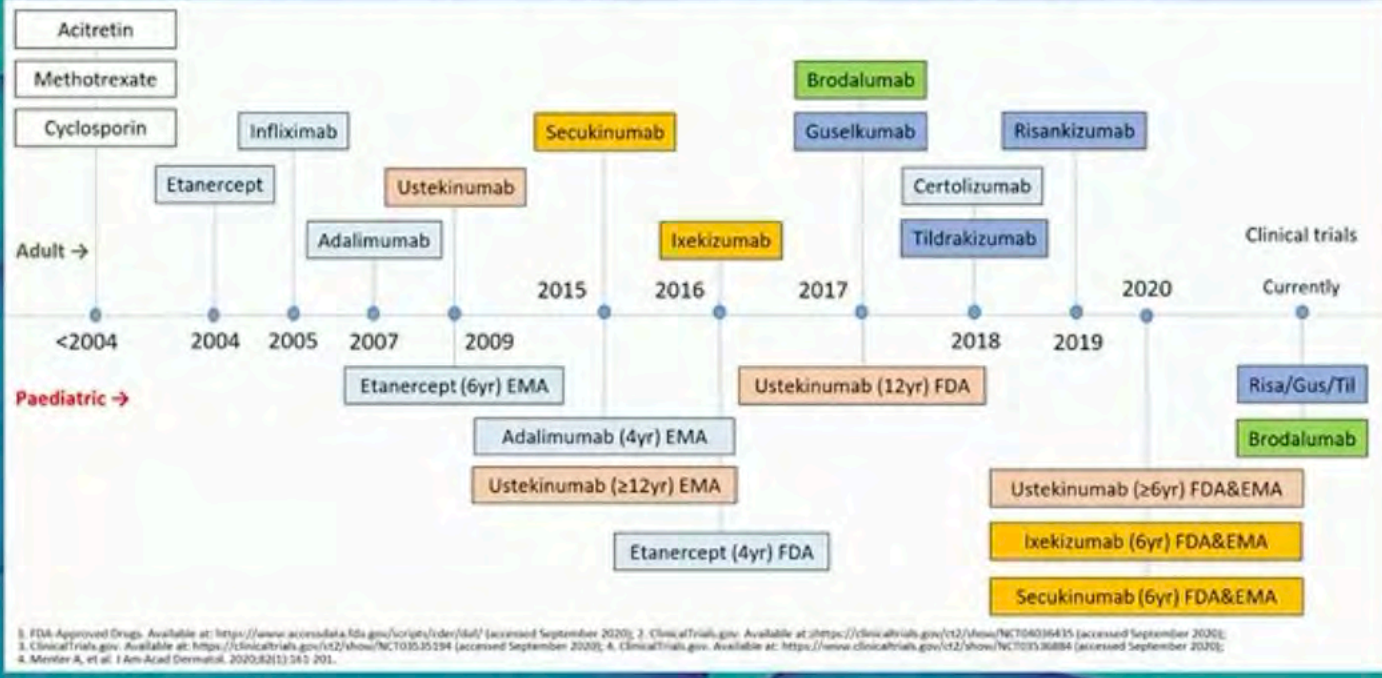


Image from: Ofidani E, et al. Curr Probl Dermatol 2013;44:17-32.

Evolving treatment landscape in adult and pediatric psoriasis
Approximately 5 years delay between approval in adult and pediatric psoriasis



Mejores resultados en PASI y EEA que tradicionales

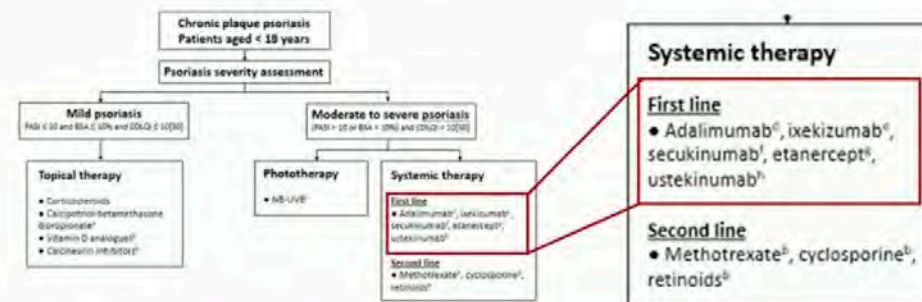
No new safety signals have been observed and safety profile was consistent with that observed in long-term studies in adults with psoriasis and children with other diseases

Biologic agents have shown a favorable safety profile in children

Should we consider biologics as first-line therapy for pediatric psoriasis?

- Biologic therapy vs conventional systemic therapy
 - Robust evidence (RCT, long-term efficacy and safety data and RWE)
 - On-label therapy
 - Higher efficacy
 - Fewer treatment-related toxic effects
 - Less monitoring
- Recommendations/guidelines proposing biologics should be considered as first-line treatment for children with severe plaque psoriasis

Etanercept, Adalimumab
Ustekinumab <<<
Secukinumab
Ixekizumab



Guideline DOI: 10.1111/ddg.13936

S2k guidelines for the treatment of psoriasis in children and adolescents – Short version part 2

Lisa Eisert¹, Matthias Augustin², Sabine Bach³, Martin Dittmann⁴, Renate Eiler⁵, Regina Fölster-Holst⁴, Sascha Gerdes⁴, Henning Hamm¹, Peter Höger⁶, Gerd Horneff⁷, Ralph von Kiedrowski⁸, Sandra Philipp⁹, Marc Pleimes¹⁰, Martin Schlaeger¹¹, Volker Schuster¹², Petra Staubach¹³, Tobias Weberschock^{14,15}, Ricardo Niklas Werner¹, Alexander Nast¹⁶, Michael Sticherling^{16*}

ORIGINAL RESEARCH

Update on the Management of Pediatric Psoriasis: An Italian Consensus

Ketty Peris · Anna Belloni Fortina · Luca Bianchi · Gabriella Fabbrocini · Paolo Gisondi · Anna Balato · Federico Bardazzi · Nicoletta Bernardini · Domenico Bonamonte · Maria Rita Bongiorno · Cinzia Bulgan · Francesco Cusano · Maria Beatrice De Felici Del Giudice · May El Hachem · Maria Concetta Fagnoli · Giulio Gualdi · Claudio Guarneri · Katharina Hansel · Giovanna Malara · Carlo Mazzalenta · Giuseppe Micali · Alessandra Narisi · Iria Neri · Teresa Oranges · Michele Panzone · Aurora Parodi · Lucia Restano · Oriana Simonetti · Marina Venturini · Vito Di Lembo

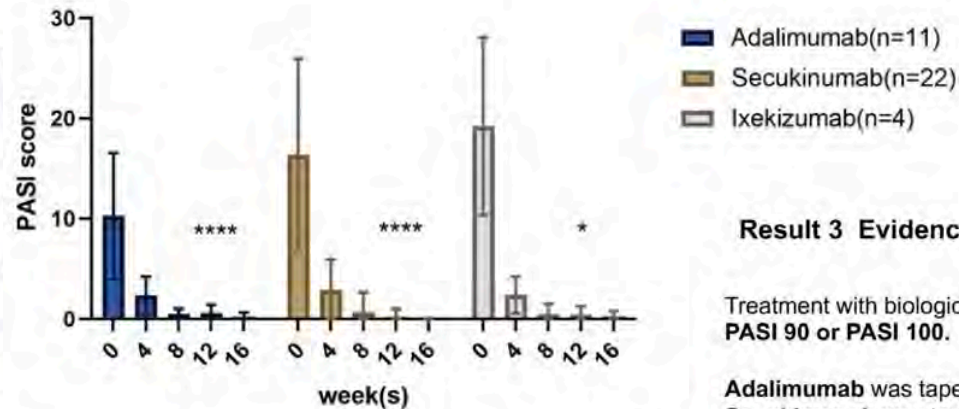
Biologic therapy	Clinical trial			Status
Brodalumab	NCT04305327	Efficacy and Safety of Brodalumab in Adolescents From 12 to 17 Years of Age With Moderate-to-severe Plaque Psoriasis	Phase 3	Early terminated due to difficulty recruiting participants
Guselkumab	NCT03451851	A Study to Evaluate the Efficacy, Safety, and Pharmacokinetics of Subcutaneously Administered Guselkumab for the Treatment of Chronic Plaque Psoriasis in Pediatric Participants	Phase 3	Recruiting
Risankizumab	NCT04435600	A Study of Subcutaneous Risankizumab Injection for Pediatric Participants With Moderate to Severe Plaque Psoriasis to Assess Change in Disease Symptoms	Phase 3	Recruiting
Tildrakizumab	NCT03997786	A Study of Tildrakizumab in Pediatric Subjects With Chronic Plaque Psoriasis	Phase 3	Recruiting
Non-biologic therapy				
Apremilast	NCT03701763	Efficacy and Safety Study of Apremilast (CC-10004) in Pediatric Subjects From 6 Through 17 Years of Age With Moderate to Severe Plaque Psoriasis	Phase 3	Completed
Deucravacitinib	NCT04772079	A Study to Evaluate the Drug Levels, Efficacy and Safety of Deucravacitinib in Pediatric Participants With Moderate to Severe Plaque Psoriasis	Phase 3	Recruiting

Dado la potencial necesidad de tratamiento a largo plazo y basado en datos de eficacia y seguridad actual, se propone que la terapia biológica debería ser considerada a día de hoy como tto de 1ªL en psoriasis pediátrica moderada-severa

Biologics for psoriasis patients under 18 years of age: Real-world evidence from the Chinese Psoriasis Real World Evidence Research Group

Yu-Xin Zheng, Xiao-Yong Man
Dermatology, Second Affiliated Hospital, Zhejiang University School of Medicine, Hangzhou, Zhejiang, China.

Efectividad y seguridad ADA, SECU, IXE



Result 3 Evidence on extending the dose interval

Treatment with biologics was initiated according to the registered standard dose and was tapered after a certain period when the patients reached PASI 90 or PASI 100.

Adalimumab was tapered from a standard dose of 40 mg Q2W to 40 mg Q4W.

Secukinumab was tapered from the standard dose 75mg/150mg/300 mg Q4W to 75mg/150mg/300 mg Q8W.

Ixekizumab dose was tapered from 80 mg Q4W to 80 mg Q8W.

In each group, 7 of 8 (87.5%) adalimumab patients, 10 of 10 (100%) secukinumab patients, and 1 of 3 (33.3%) ixekizumab patients could successfully prolong their dosing interval maintaining PASI 90 or above and the absolute PASI score < 3 for at least 6 months.

CONCLUSION

1. Biologics is efficacy and safe for children with psoriasis.
2. Switching between TNF α antagonists, or switching from TNF α antagonists to IL-17A antagonists are both effective and safe.
3. Extending the dosing interval is safe for most patients.

- *Fungal infections of the scalp - current treatment algorithm*
Prof. Jacob Mashiah (Tel Aviv, Israel)



TEL AVIV SOURASKY
MEDICAL CENTER
ICHILOV

Fungal Infections
of the Scalp

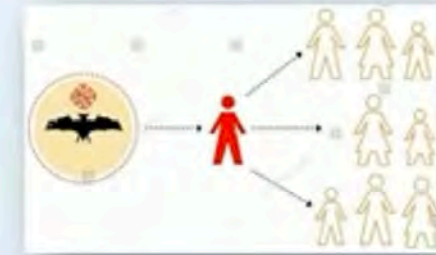DANA
DANA DWEX Children's Hospital

Jacob Mashiah
Dermatology and Pediatric Dermatology
Dana-Dwek children's hospital
Tel-Aviv Sourasky Medical Center Tel-Aviv, Israel



Carrier state

- **Colonization with dermatophytes without symptoms**
- Reservoir, source of transmission of disease.
- In a study 32% of families with an infected child had at least one carrier, of whom 13% still positive six months later
- Asymptomatic carriers are source of transmission:
 - Household members, residential schools, day-care cent
- More likely with anthropophilic species – minimal infla
- May persist 6w-6m in 10-25% untreated carriers



Screening within the family

- Systemic treatment is indicated only if clinical signs exist
- Asymptomatic contacts should use antifungal shampoos

Contaminated objects treatment

Management

- Children receiving treatment can attend school
- Not necessary to have haircut, or to wear a hat
- Topical antifungal shampoo is advised In order to prevent spread and for better cure



Tinea Capitis Treatment

▪ Griseofulvin

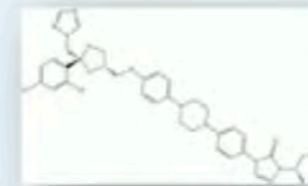
- Has served as first-line therapy for more than 40 years because of its efficacy, safety
- Decrease in sensitivity to this agent appears to have developed.
- Significant number of failures in those treated with 10 mg/kg per day
- Should be preferred for *Microsporum* infections

▪ Terbinafin

- The only FDA approved therapeutic alternative to griseofulvin for tinea capitis
- Should be preferred for *Trichophyton* infections

▪ Itraconazole, and fluconazole

- Growing evidence of their efficacy
- One study showed suboptimal results for Fluconazole
- May require short-course therapies than griseofulvin



Tinea Capitis Treatment

▪ **Kerion treatment**

- Systemic antifungal agents + oral prednisone, 1–2 mg/kg per day for 10–14 days
- Antibacterial agents usually not indicated, except:
 - Bacterial infection is clearly demonstrated
 - Failure of antifungal therapy

▪ **Dermatophytid reactions**

- Can develop with antifungal treatment commencement
- Often requires either topical or systemic corticosteroid therapy

▪ **Photodynamic therapy**

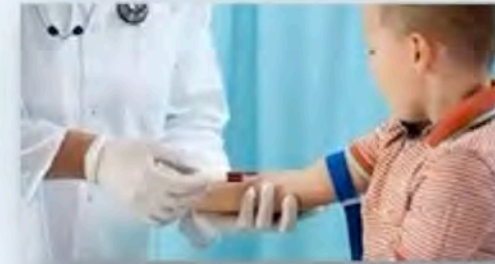- Alternative off-label treatment
- In combination with topical adjuvant
- Large thoroughly conducted clinical trials are needed



Laboratory monitoring during antifungal treatment **yes or no**


- Systemic antifungal therapy is considered safe yet can be hepatotoxic
- There is a great differences of opinion regarding the need of laboratory monitoring

- **Some recommend: Laboratory monitoring prior to treatment and every 4w:**
 - History of impaired liver function, or comorbidities affecting liver function
 - Those taking other hepatotoxic drugs



- **Our experience:**
 - 321 children, (70%) griseofulvin, (30%) terbinafine.
 - 64 (20%) had hematologic or hepatic laboratory test abnormalities
 - (96.3%) were considered as mild
 - No difference in laboratory abnormalities between griseofulvin and terbinafine groups
 - In one patient increased aminotransferases required treatment discontinuation

- **Our practice:**
 - In light of the age group of our patients and substantial, although mild, lab test abn
 - We do perform laboratory monitoring tests prior to treatment and every 4w



Aleohin et

Introducing a Novel SQLE Mutation in Terbinafine-Resistant *T. indotinea* Isolates among Individuals with Recalcitrant Dermatophytosis from Iran

Mahsa Fattahi¹ Ph.D.; Shayan Zamani¹ M.D.; Alireza Firooz M.D.^{1*}

¹. Center for Research and Training in Skin Diseases and Leprosy, Tehran University of Medical Sciences, Tehran, Iran

Background and Aim

Results

Conclusions

Our study revealed a considerable level of terbinafine resistance in clinical samples which is a serious warning for patients vulnerable to dermatophytosis. Our findings have also revealed a different mutation pattern in the SQLE gene. Present outcome emphasizes on continuous evolution and development of novel mechanisms of terbinafine resistance in clinical *T. indotinea* isolates. Analyzing the outline of resistance of *T. indotinea* isolates could therefore make a chance for prediction of regional resistance status, and possible future epidemiological changes that can help breaking the resistance chain; either through reinforcing anti fungal stewardship guidelines or designing new antifungals with different target site.

Contact

The Novel Treatment of Children with Recalcitrant Viral Warts using Microwave Technology

Rachel Solomon & Vincent Hip

Alder Hey Children's NHS Foundation Trust, Liverpool, UK




Figure 1. Microwave therapy for wart removal

Characteristics	Resolved (n = 24)	Not Resolved (n = 11)
Sex (n)		
Male	13 (54%)	4 (36%)
Female	11 (46%)	7 (64%)
Age (years)		
Mean (Range)	12 (6-17)	12 (6-19)
Duration of warts (months)		
Mean (median)	29 (24)	31 (36)
Previous treatments (n)		
Topicals	17	10
Cantharidin	11	5
Cryotherapy	2	1
Nil	2	0
Number of treatment areas		
Mean (range)	2 (1-3)	2 (1-4)
Number of treatment sessions		
Mean (range)	3 (1-8)	4 (1-6)
Tolerability		
Tolerated	20 (83%)	7 (64%)
Not tolerated	4 (17%)	4 (36%)

- Microwave therapy is an effective and well tolerated treatment modality for recalcitrant viral warts in children.
- In our cohort, 20 patients presented with plantar warts and clearance was achieved in 70% (14/20) of cases. This compares favourably to salicylic acid and cryotherapy which achieved clearance in 31% and 34% of patients, respectively.⁵
- There were no reports of ulceration, blistering or pigmentary changes.
- An acute short-lived pain was reported during treatment that led to discontinuation in some patients. Adjusting the energy settings and duration of the device improved tolerability.
- Microwave therapy is quick, without the need for specialist pre- or post-treatment care and does not generate surgical plume which can be harmful to operators.
- Further randomised studies with larger sample sizes are warranted to confirm our findings.

The novel treatment of children with molluscum contagiosum using microwave technology

Mirno Gaastra, MD
1Centrum Oosterwal, Comeniusstraat 3, 1817 MS Alkmaar, Netherlands



Summary

- Feasibility case series to use microwave technology to treat molluscum contagiosum
- 100% clearance within 1 to 2 treatments
- Only a small subset of lesions treated, but all cleared
- Quick and easy treatment modality
- Minimal acute treatment pain, no blistering, no aftercare

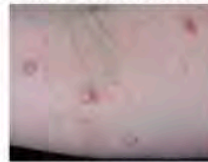

Fig. 1: MC lesions on the right elbow. Photo courtesy of D. Cronkwright B.Pod (Hons), Geelong Wart Clinic

Introduction

- Molluscum contagiosum (MC) is an easily transmitted pox virus commonly found in children and the immunosuppressed¹
- Multiple individual benign papules associated with itching, pain, and inflammation (Fig. 1)
- Although self-limiting, auto-inoculation can result in the lesions being present for months to years due to the virus' innate ability to hide from the host immune system²
- Recent Cochrane review concluded that no single intervention has been shown to be convincingly effective in the treatment of MC³
- No EMA/MHRA-approved treatments (Tx) available in Europe and the UK

Results

- Atopic family history of asthma, bronchitis, hay fever, or eczema
- Failed prior Tx for their MC using different over-the-counter products.

	Patient 1:	1x		2W, 2s, 3 repeats	⇒	100% resolution
	Patient 2:	2x		2W, 2s, 3 repeats	⇒	100% resolution
	Patient 3:	2x		2W, 2s, 4 repeats	⇒	100% resolution
	Patient 4:	1x		2W, 2s, 3 repeats	⇒	100% resolution
	Patient 5:	2x		2W, 2s, 3 repeats	⇒	100% resolution

- Systemic immune response is suggested (subset treated, all resolved)
- Microwave Tx can induce acute pain for 1-2s → Tx very well tolerated by children
- Patients & parents “very happy” with microwave therapy outcome

Conclusion

CHILDHOOD GRANULOMATOUS PERIORIFICAL DERMATITIS EXPLORING NOVEL APPROACHES FOR MANAGEMENT

Madalena Pupo Correia¹, Catarina Correia¹, Sónia Fernandes^{1,2}, Pedro de Vasconcelos¹, Luís Soares de Almeida^{1,2}, Paulo Filipe^{1,2}
1. Dermatology Department, Hospital de Santa Maria, Centro Hospitalar Universitário Lisboa Norte, Lisbon, Portugal
2. Lisbon University Clinic of Dermatology, Faculdade de Medicina da Universidade de Lisboa, Lisbon, Portugal

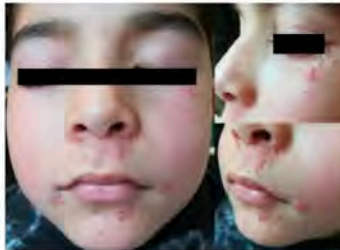INTRODUCTION

Childhood granulomatous periorifical dermatitis was first reported in 1970 by Gianotti et al. is thought to be an uncommon variant of perioral dermatitis. The **diagnosis** is based on clinical presentation (flesh-coloured papules without vesicles or pustules distributed by periorifical areas of the face) and the presence of a perifollicular granulomatous infiltrate on histopathology

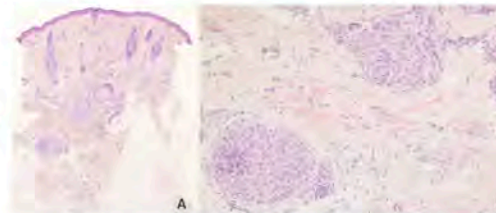
Due to its **benign and self-limiting course**, treatment is not mandatory. When it imposes a significant impact on the wellbeing of the child, **treatment** with topical metronidazole and, depending on age, tetracyclines and erythromycin may be efficacious. The first step in management should be discontinuation of all topical corticosteroids, as **rebound flaring** is often seen when stopping them.

CASE REPORT

- ❑ 9-year-old portuguese boy
- ❑ Consecutive appearance of persistent asymptomatic erythematous micropapules appearing consecutively around the nose, eyes, and mouth in the last 8 months
- ❑ **Previous treatments:** oral clarithromycin, topical and systemic corticosteroids, pimecrolimus cream, boric acid solution, and emollients
- ❑ **Medical history:** asthma
- ❑ **Current treatments:** daily inhaled salmeterol/fluticasone and oral montelukast



Picture 1. Clinical features in the first appointment at our clinic



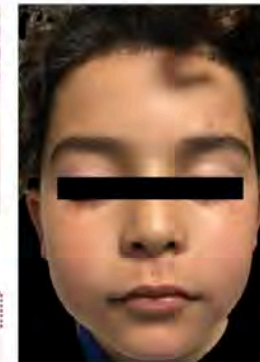
Picture 2. skin biopsy from the perioral area (A - H&E, x40), (B - H&E, x100)

Gram stain was negative

DIAGNOSIS: CHILDHOOD GRANULOMATOUS PERIORIFICAL DERMATITIS

TREATMENT with topical tacrolimus and ivermectin led to significant improvement, although some periorifical millimeter-sized papules persisted

- ❑ After adding a single oral dose of ivermectin (214 µg/kg) there was an almost complete clearance of skin lesions

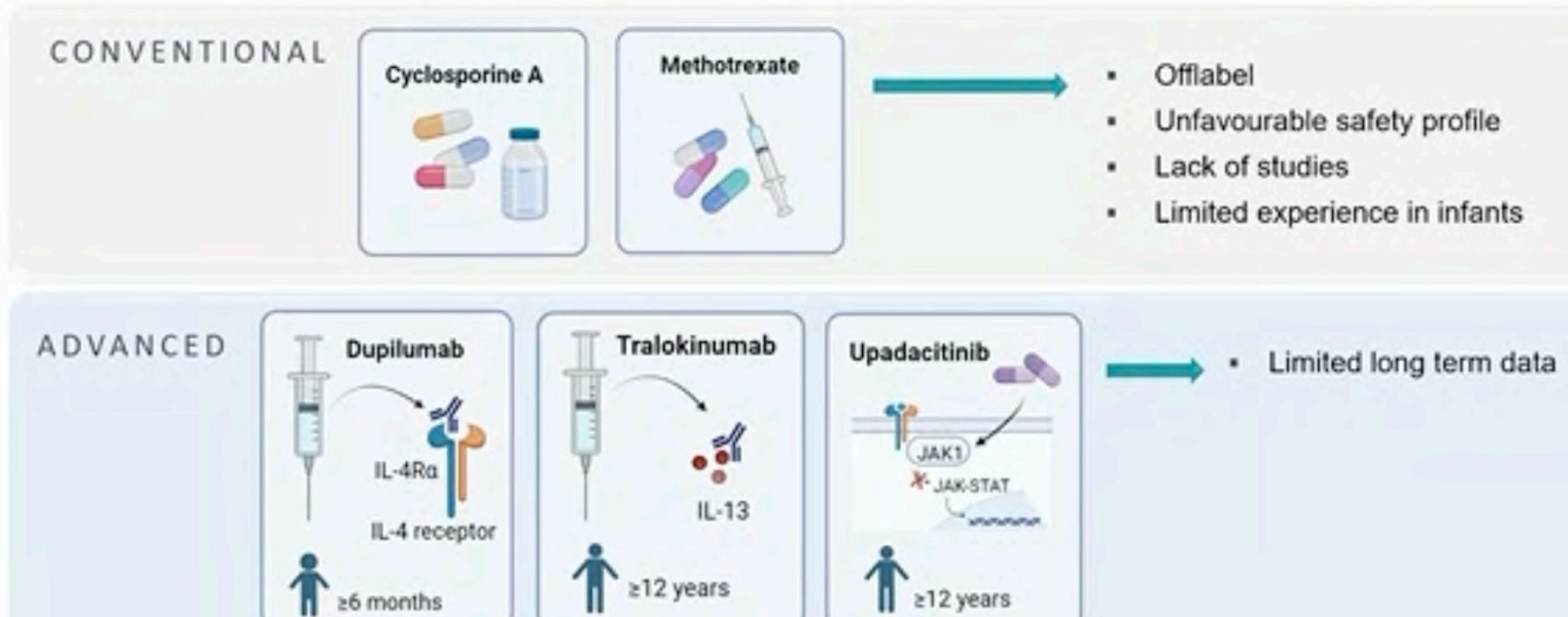


Picture 3. 1 month after oral ivermectin

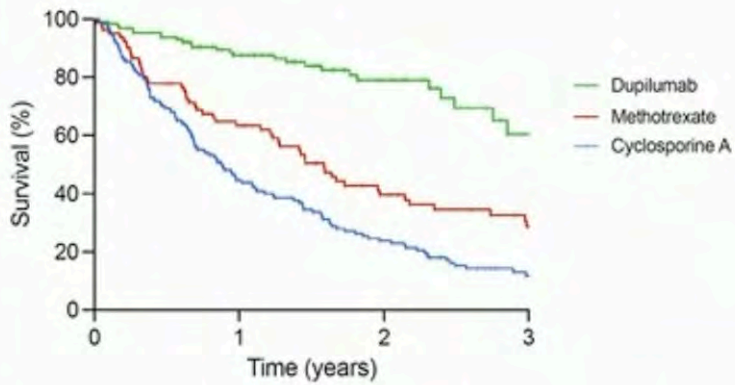
Ivermectina oral en monodosis (214ug/kg) eficaz en refractarios a ivermectina y tacrólimus tópico

- *Management of paediatric atopic dermatitis*
Dr. Marlies De Graaf (Utrecht, Netherlands)

Current systemic treatments for pediatric AD



Overall drug survival



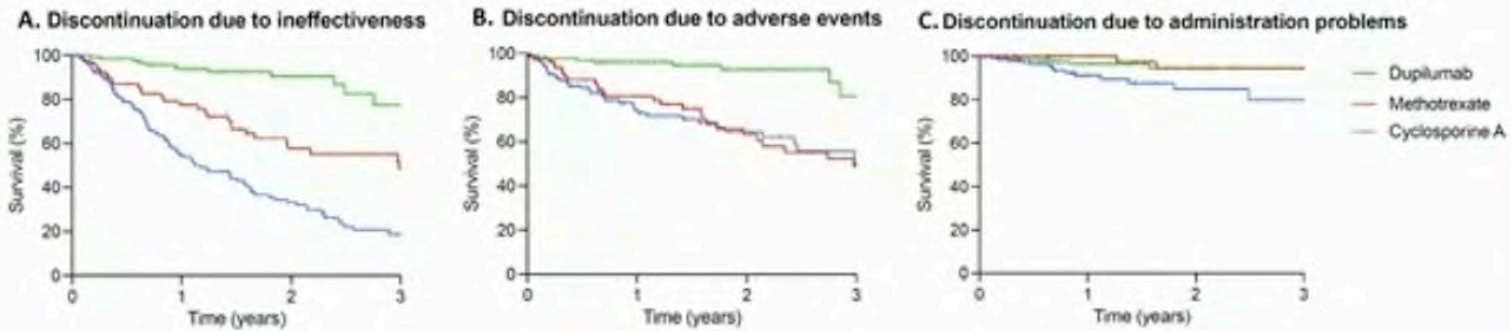
Survival	Totaal
Dupilumab (n)	128 (27 stopped)*
1 year (%)	87.6
2 years (%)	79.0
3 years (%)	65.1
CsA (n)	173 (138 stopped)*
1 year (%)	44.6
2 years (%)	23.8
3 years (%)	11.7
MTX (n)	82 (55 stopped)*
1 year (%)	63.4
2 years (%)	39.6
3 years (%)	28.8

*Censored for well-controlled disease and lost-to-follow-up.
Van der Rijst et al. Manuscript in preparation.

Data of 3/5 centers are presented.

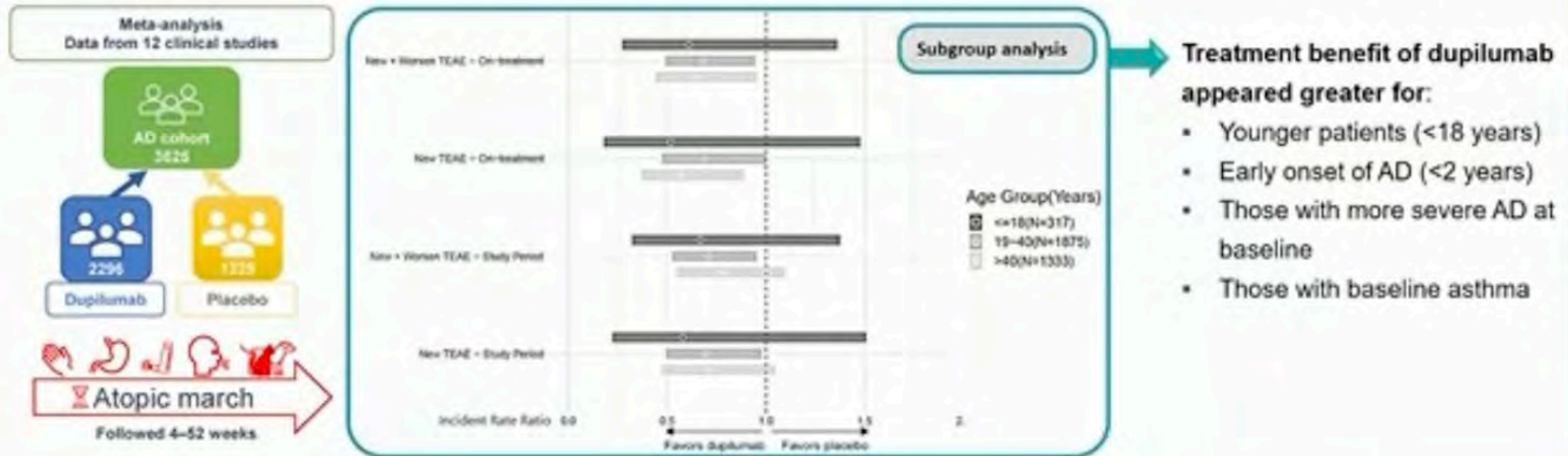
Marlies D
Management of
dermatitis

Reasons for discontinuation



Attenuating the Atopic March:

Meta-analysis of the dupilumab atopic dermatitis database for incident allergic events



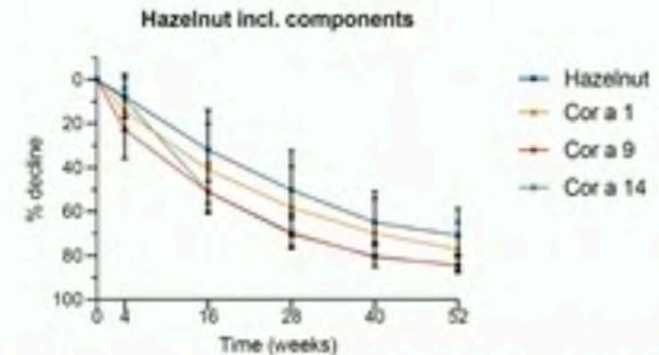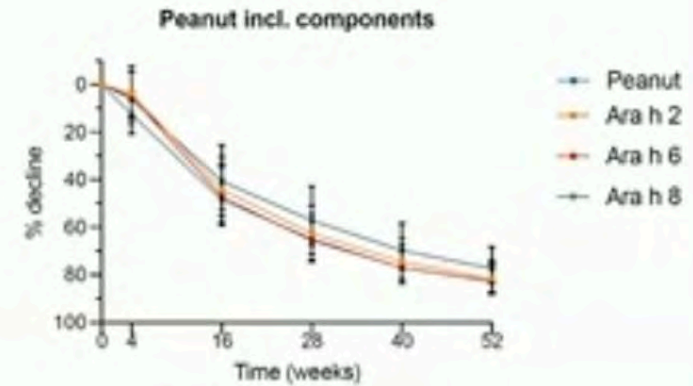
Impact on Atopy –

Food Allergy

36 patients included


- N=1008 sIgE samples

↓ 70.5% to 82.5% after 52 weeks



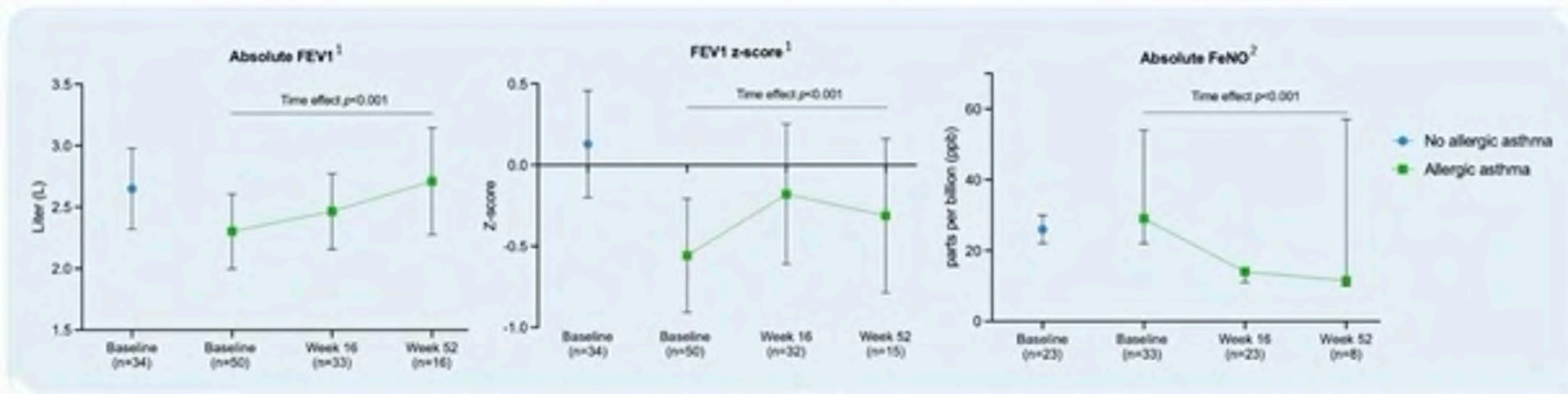
Decline representative for all food allergens (peanut, hazelnut, cashew nut, almond, pistachio, walnut, kiwi, apple, cow's milk and hen's egg)

Impact on Atopy –

Asthma 

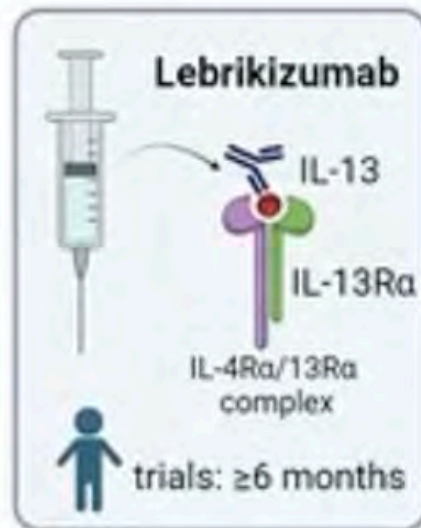
84 patients included

- 59.5% (n=50) diagnosed with allergic asthma
 - 7/50 (14%) patients with newly diagnosed allergic asthma (median age: 12.0 [range: 4-17])



¹Bars represent means and the 95% CI. ²Bars represent medians and the 95% CI. FEV1, Forced Expiratory Volume in 1 second; FeNO, Fractional exhaled Nitric Oxide; Ppb, parts per billion. P-values based on overall likelihood ratio tests for time.

Future for pediatric patients with AD: lebrikizumab

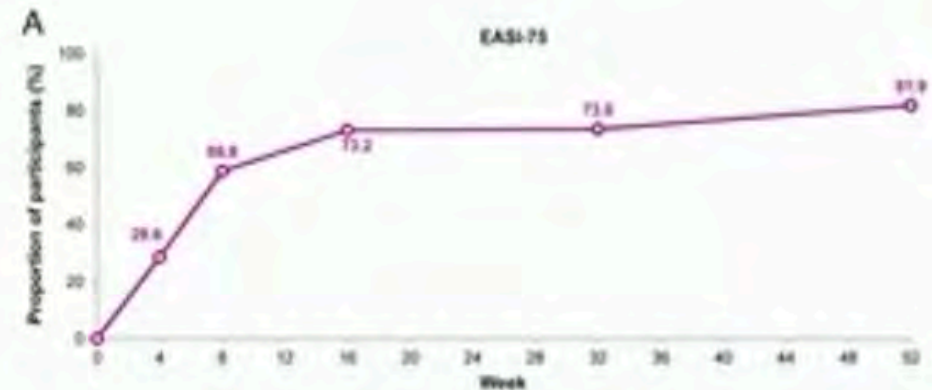

Recent publication:

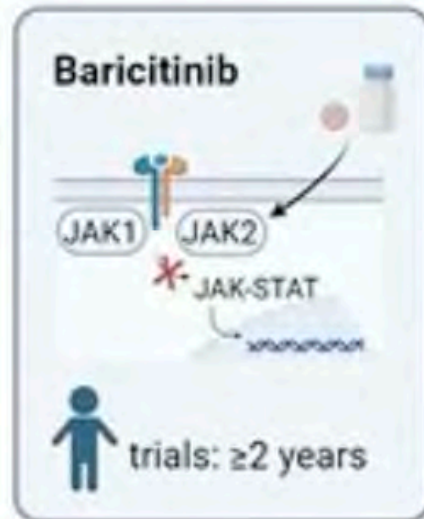
Paller et al. 2023. Trials: ADvocate 1, ADvocate 2, Adhere

- Lebrikizumab 250 mg Q2W
- ≥12-17 years (n=206)
- 52 weeks of treatment
- 2.4% AEs leading to treatment discontinuation, 2.4% SAEs

➔ 81.9% achieved EASI-75 at W52



Future for pediatric patients with AD: baricitinib

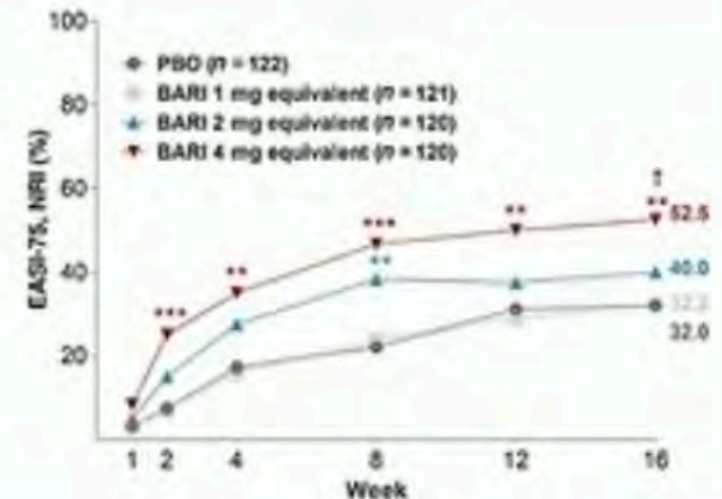


Recent publication:

Torrelo et al. 2023. Trial: BREEZE-AD PEDS

- Baricitinib 1mg/2mg/4mg vs placebo
- ≥ 2 -17 years (n=483)
- 16 weeks of treatment
- 0.6% AEs leading to treatment discontinuation, 1.1% SAEs

➔ 32.2-52.5% achieved EASI-75 at W16





UCC

Coláiste na hOllscoile Corcaigh, Éire
University College Cork, Ireland

Sleep in Infants with early-onset atopic Dermatitis by Longitudinal Evaluation The SPINDLE study

O'Connor C ^{1,2}, Ventura S ^{1,2}, O'Sullivan M, ¹ Irvine A ^{1,3}, Murray D ^{1,2}, Hourihane J ^{1,4}, Murphy M ⁵, Boylan G ^{1,2}

¹ INFANT Research Centre, University College Cork, Cork ² Department of Paediatrics and Child Health, Cork University Hospital, Cork
³ Dermatology, CHI at Crumlin; Clinical Medicine, Trinity College Dublin ⁴ Paediatric Allergy, CHI at Temple St; Paediatrics, Royal College of Surgeons of Ireland, Dublin
⁵ Dermatology, South Infirmary Victoria University Hospital; Medicine, University College Cork



RESULTS – QUANTITATIVE

INFANT SLEEP - QUANTITATIVE



6 months	Sleep latency (min)	Waking (n)	Total sleep time (hours)	'Major problem' (%)
Cases (n=32)	22.3	3.5	13.1	16.1%
Controls (n=31)	15.8	1.9	13.8	5.4%
	p<0.05	p<0.05	p<0.05	p<0.05

Babies with eczema wake 2x overnight as babies without eczema

MATERNAL SLEEP - QUANTITATIVE



Mother sleep less, take longer to fall asleep

6 months	Sleep latency (min)	Time in bed (hours)	Total sleep time (hours)	Sleep efficiency (%)
Cases (n=32)	27.1	8.3	6	72
Controls (n=31)	12.8	8.38	7.3	88
	p<0.05		p<0.05	p<0.05

Fathers – no difference

Afectación sueño, tanto pacientes como padres
Carga indirecta de enfermedad

RESULTS – QUALITATIVE

Inflammatory cytokine analysis using tape stripping. In addition to the skin barrier assessments, clinical severity scoring

and filaggrin mutational testing was performed for cases.

O'Connor et al. BMC Pediatrics (2022) 22:352
<https://doi.org/10.1186/s12887-022-03382-3>

BMC Pediatrics

STUDY PROTOCOL

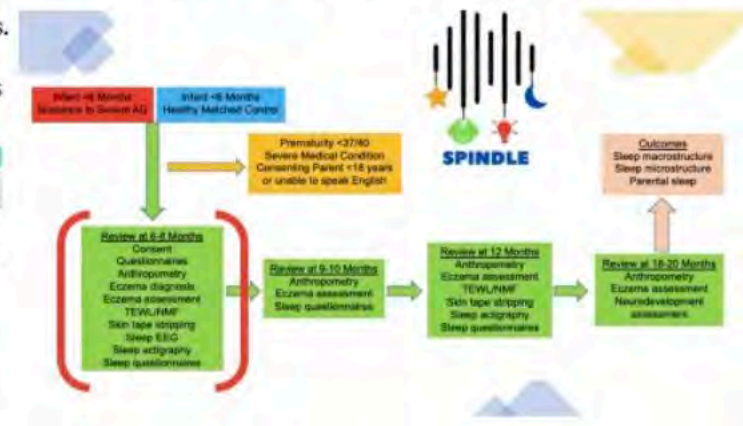
Open Access

Study protocol: assessing Sleep IN infants with early-onset atopic Dermatitis by Longitudinal Evaluation (The SPINDLE study)

Cathal O'Connor^{1,2,3*}, Alan D. Irvine^{1,3}, Deirdre Murray^{1,4}, Michelle Murphy^{2,5}, Jonathan O'S Hourihane^{1,3} and Geraldine Boylan^{1,2}

Trial registration

clinicaltrials.gov/NCT05031754, retrospectively registered on September 2nd, 2021.



Atopic dermatitis in childhood and subsequent pubertal development: A nationwide cohort study

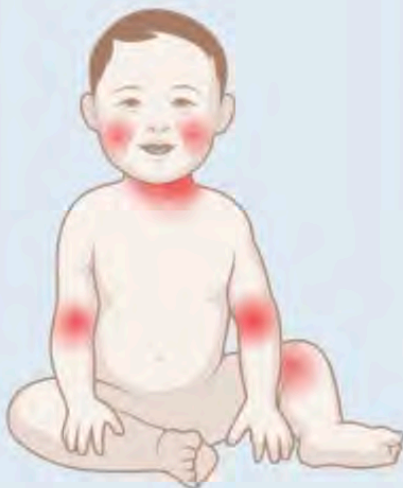Camilla Lomholt Kjersgaard, MD¹, Andreas Ernst, MD, PhD^{1,2}, Lea Lykke Harrits Lunddorf MD, PhD¹, Linn Håkonsen Arendt MD, PhD^{1,3}, Nis Brix MD, PhD^{1,4},

Onyebuchi A. Arah, MD, PhD^{1,5}, Mette Deleuran, M

¹Department of Public Health, Research Unit for Epidemiology, Aarhus University, Aarhus, Denmark. ²Department of Urology, Aarhus U. ³Department of Clinical Genetics, Aarhus University Hospital, Aarhus, Denmark. ⁴Department of Epidemiology, Fielding School of Public H

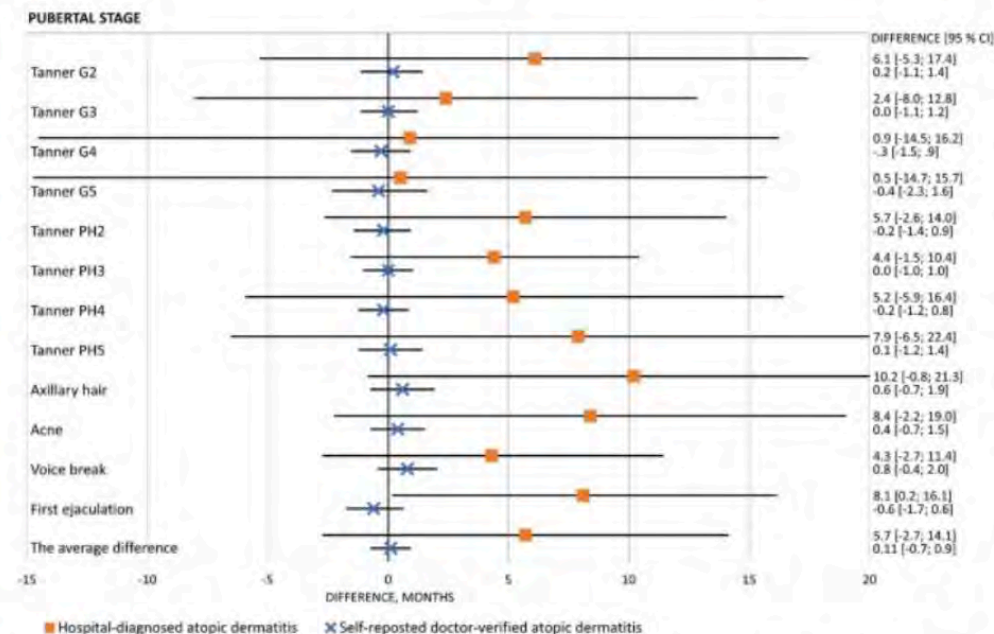
Boys with hospital-
diagnosed
atopic dermatitis
had a later pubertal
development than
their unaffected
peers

No
efecto
en niñas



RESULTS - preliminary

Age difference in months in pubertal development according to atopic dermatitis among 7,563 boys in the Puberty Cohort, Danish National Birth Cohort, Denmark, 2012-2021



Notes: Estimated age differences in pubertal development with 95 % confidence intervals (CIs). The reference was boys without atopic dermatitis and the analyses were adjusted for maternal age at menarche, maternal body mass index (BMI), maternal smoking during pregnancy, cohabitation of parents during pregnancy, and socioeconomic status of parents. G2-5, genital stages 2-5; PH2-5, pubic hair stages

CONCLUSION

Boys with hospital-diagnosed atopic dermatitis had a later pubertal development than their unaffected peers, but with confidence intervals including the null. We did not find any relationship between atopic dermatitis and pubertal development in girls and self-reported doctor-verified atopic dermatitis in boys.

Long-Term Efficacy and Safety of Dupilumab Treatment in Children Aged 6 Months to 5 Years with Severe Atopic Dermatitis Enrolled in an Open-Label Extension Study

Amy S. Paller^{1,2}, Andreas Pinter³, Lawrence F. Eichenfield^{4,5}, Lara Wine Lee⁶, Roland Aschoff⁷, Jacek Zdybski⁸, Christina Schnopp⁹, Amy Praestgaard¹⁰, Ashish Bansal¹¹, Brad Shumel¹¹, Randy Prescilla¹⁰, Mike Bastian¹²

¹Northwestern University Feinberg School of Medicine, Chicago, IL, USA; ²Ann and Robert H. Lurie Children's Hospital, Chicago, IL, USA; ³University Hospital Frankfurt am Main, Frankfurt am Main, Germany; ⁴University of California, San Diego, CA, USA; ⁵Rady Children's Hospital, San Diego, CA, USA; ⁶...



RESULTS (CONT.)

Table 2. Patient treatment exposure.

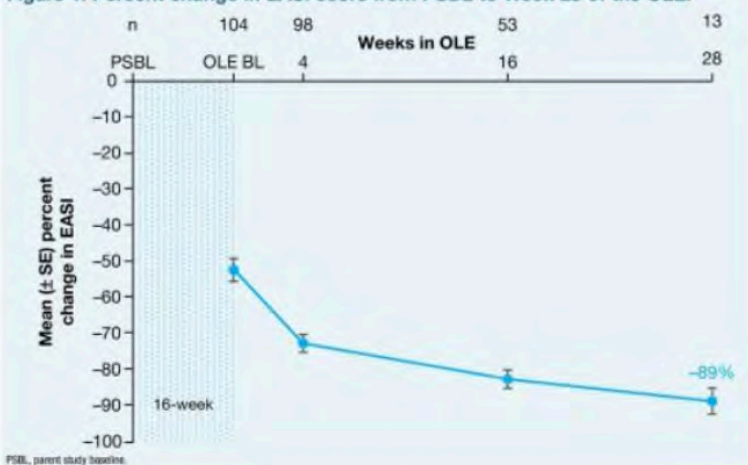
	Dupilumab 200/300 mg q4w (N = 104)
Treatment exposure, mean (SD), weeks	17.4 (7.3)
Patients with overall treatment exposure, n (%), weeks	
4 to <16 weeks	46 (44.2)
16 to <28 weeks	47 (45.2)

Table 3. Summary of TEAEs.

	Dupilumab 200/300 mg q4w (N = 104)
Patients with any TEAE	55 (52.9)
Patients with any serious TEAE	0
Patients with any severe TEAE	2 (1.9)
Patients with any TEAEs related to treatment	7 (6.7)
Patients with any TEAEs leading to permanent discontinuation	1 (1.0)

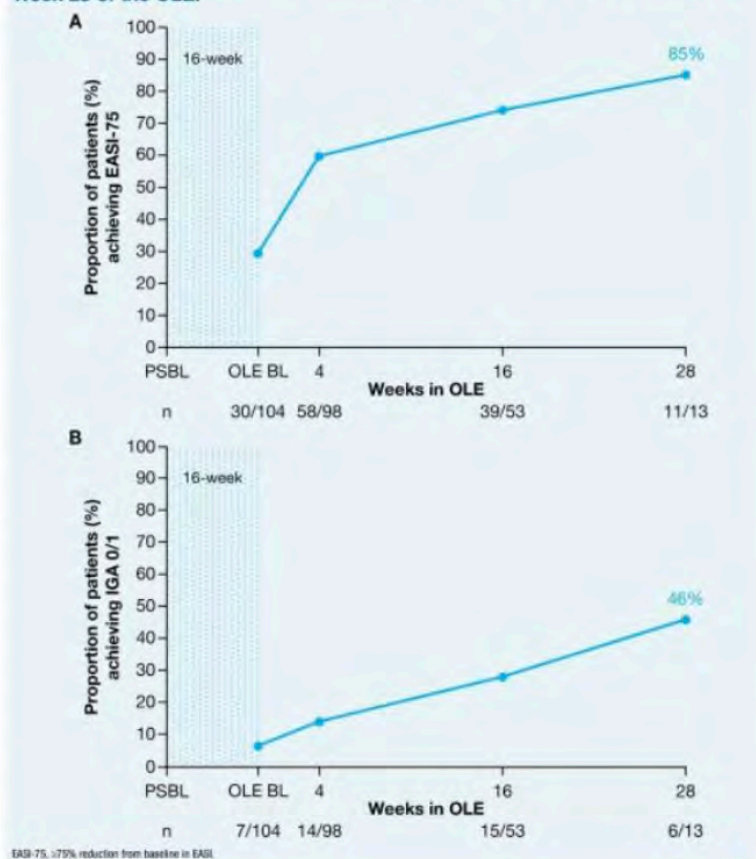
All data are expressed as n (%); n/N (%); number of patients per 100-patient years; TEAE, treatment-emergent adverse event.

Figure 1. Percent change in EASI score from PSBL to Week 28 of the OLE.



PSBL, parent study baseline.

Figure 2. Proportion of patients achieving (A) EASI-75 and (B) IGA 0/1 through to Week 28 of the OLE.



EASI-75, >75% reduction from baseline in EASI.

Buenos resultados a largo plazo en subgrupo de 6m a 5 años (ya aprobado)

CONCLUSIONS

- Long-term dupilumab treatment showed sustained improvement of AD signs in children aged 6 months to 5 years with severe AD
- Consistent with results seen in adults, adolescents, and children aged 6 years and older, long-term treatment with dupilumab in children aged 6 months to 5 years with severe AD showed an acceptable safety profile

Dupilumab Reduces Inflammatory Biomarkers in Patients Aged 6 Months to 17 Years With Moderate-to-Severe or Severe Atopic Dermatitis

Lisa A. Beck¹, Antonella Muraro², Mark Boguniewicz^{3,4}, Zhen Chen⁵, Peter Zoob⁵, Ainara Rodríguez Marco⁶

¹University of Rochester Medical Center, Rochester, NY, USA; ²Food Allergy Referral Centre, Padua University Hospital, Padua, Italy; ³National Jewish Health, Denver, CO, USA; ⁴University of Colorado School of Medicine, Denver, CO, USA; ⁵Regeneron Pharmaceuticals Inc., Tarrytown, NY, USA; ⁶Sanofi, Madrid, Spain

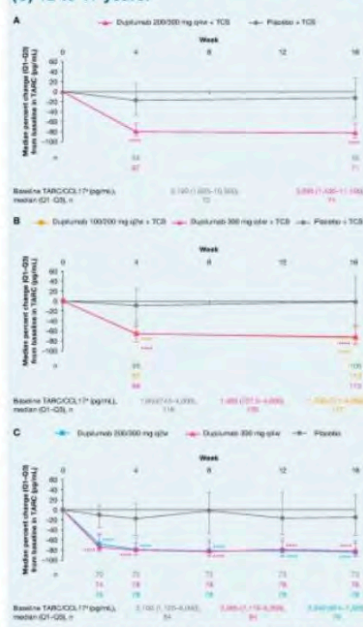
INTRODUCTION

RESULTS

Posibilidad
reducción
inflamación
sistémica:
¿reversión de
la marcha
atópica?


RESULTS

Figure 1. Percent changes in serum TARC/CCL17 levels over time among patients aged (A) 6 months to 5 years, (B) 6 to 11 years, and (C) 12 to 17 years.



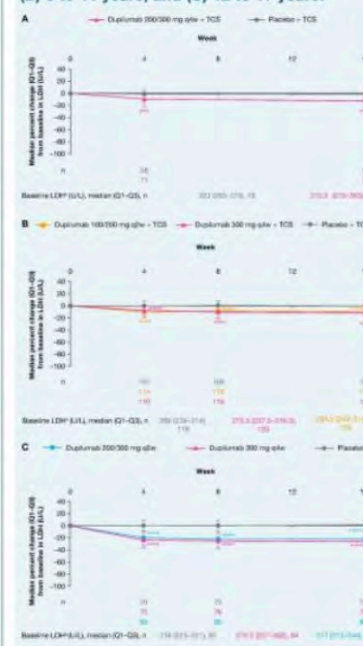
P value for placebo = 0.0001. *P value for placebo = 0.0001. The P value was based on treatment difference (dupilumab or dupilumab groups vs placebo) of the median change using rank-based ANCOVA model with baseline measurement as covariate and the treatment or treatment and baseline USA data in patients aged 12 to 17 years as fixed factors. LOCF method consisting after rescue treatment was used. ANCOVA analysis of covariance (USA, investigator's Global Assessment), LDH, and observation carried forward.

Figure 2. Total IgE levels over time among patients aged (A) 6 months to 5 years, (B) 6 to 11 years, and (C) 12 to 17 years.



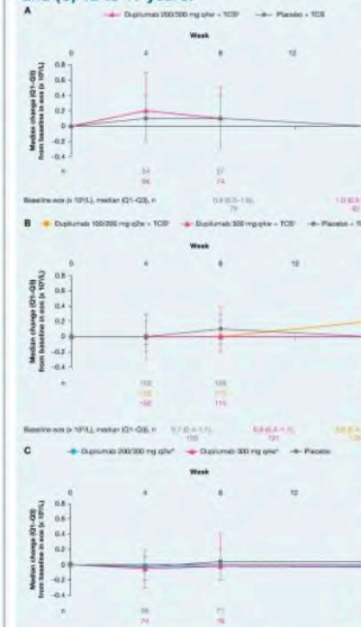
****P value for dupilumab vs placebo change from baseline = 0.0001. Last observation carried forward method consisting after rescue treatment was used. The P value was based on treatment difference (dupilumab groups vs placebo) of the median change using rank-based ANCOVA model with baseline measurement as covariate and the treatment as fixed factor.

Figure 3. Percent changes in LDH over time among patients aged (A) 6 months to 5 years, (B) 6 to 11 years, and (C) 12 to 17 years.



P value for placebo = 0.0001. *P value for placebo = 0.0001. The P value was based on treatment difference (dupilumab or dupilumab groups vs placebo) of the median change using rank-based ANCOVA model with baseline measurement as covariate and the treatment or treatment and baseline USA data in patients aged 12 to 17 years as fixed factors. LOCF method consisting after rescue treatment was used.

Figure 4. Change from baseline in eosinophil levels over time among patients aged (A) 6 months to 5 years, (B) 6 to 11 years, and (C) 12 to 17 years.



P value for placebo = 0.0001. *P value for placebo = 0.0001. The P value was based on treatment difference (dupilumab or dupilumab groups vs placebo) of the median change using rank-based ANCOVA model with baseline measurement as covariate and the treatment or treatment and baseline USA data in patients aged 12 to 17 years as fixed factors. LOCF method consisting after rescue treatment was used. P value at Week 16 vs placebo: 0.0001, 0.0001, 0.0001.

CONCLUSIONS

- Dupilumab treatment for 16 weeks in patients aged 6 months to 17 years with moderate-to-severe or severe AD reduces levels of type 2 and general inflammatory biomarkers TARC/CCL17, LDH, and total IgE
- The changes in eosinophil levels were not clinically meaningful

Long-Term Safety of Upadacitinib in Atopic Dermatitis Stratified by Age

Jonathan I. Silverberg,¹ Christopher G. Bunick,² Eric L. Simpson,³ Linda Stein Gold,⁴ Emma Guttman-Yassky,⁵ Mark Boguniewicz,⁶ Andrew Blauvelt,⁷ Juan Francisco Silvestre Salvador,⁸ H. Chih-Ho Hong,⁹ Henrique D. Teixeira,¹⁰ Smitha Suravaram,¹⁰ Deanne Dilley,¹⁰ Cristina Sancho,¹¹ Ayman Grada,¹⁰ Kilian Eyerich¹²

¹Department of Dermatology, The George Washington University School of Medicine and Health Sciences, Washington, DC, USA; ²Department of Dermatology, Yale School of Medicine, New Haven, CT, USA; ³Department of Dermatology, Oregon Health and Science University, Portland, OR, USA; ⁴Henry Ford Health System, Detroit, MI, USA; ⁵Department of Dermatology, Icahn School of Medicine at Mount Sinai, New York, NY, USA; ⁶Department of Pediatrics, National Jewish Health and University of Colorado School of Medicine, Denver, CO, USA; ⁷Oregon Medical Research Center, Portland, OR, USA; ⁸Department of Dermatology, Hospital General de Alicante, Alicante, Spain; ⁹Department of Dermatology and Skin Science, University of British Columbia, and Priddy Medical Research, Surrey, BC, Canada; ¹⁰AbbVie Inc., North Chicago, IL, USA; ¹¹AbbVie, Madrid, Spain; ¹²Department of Dermatology and Venereology, Medical Center, University of Freiburg, Freiburg im Breisgau, Germany

Mínimos EEAA y similar en adultos

Table 2. Overview of Treatment-Emergent AESI in Exposure-Adjusted Rate per 100 PY by Age Group for Patients in the United States

AESI	All Patients		12-17 years		18-39 years		40-64 years		<65 years		≥65 years	
	15 mg	30 mg	15 mg	30 mg	15 mg	30 mg	15 mg	30 mg	15 mg	30 mg	15 mg	30 mg
N	330	320	73	77	129	105	101	93	303	275	36	45
Exposure (PY)	721.7	708.1	133.3	172.2	275.5	229.9	241.0	203.9	649.8	606.0	71.8	102.1
Events (E/100 PY)												
Serious infections	2.4	2.7	3.0	0	2.5	0.9	1.2	3.9	2.2	1.7	4.2	8.8
Opportunistic infection (excl. TB/herpes zoster)	1.4	0.8	2.3	1.2	1.8	1.3	0.8	0	1.5	0.8	0	1.0
Active TB	0	0	0	0	0	0	0	0	0	0	0	0
Herpes zoster	1.7	2.0	0	0	2.5	0.9	1.7	4.4	1.7	1.8	1.4	2.9
Malignancy excl. NMSC*	0.3	0.4	0	0	0	0	0.4	1.0	0.2	0.3	1.4	1.0
NMSC*	0.4	0.6	0	0	0	0	0.8	1.5	0.3	0.5	1.4	1.0
MACE*	0.3	0.1	0	0	0	0	0.4	0	0.2	0	1.4	1.0
VTE*	0.3	0.3	0	0	0	0	0.4	0.5	0.2	0.2	1.4	1.0
Gastric perforation	0	0	0	0	0	0	0	0	0	0	0	0
AE leading to death	0	0.3	0	0	0	0	0	0.5	0	0.2	0	1.0

AESI, adverse events of special interest; E, event; MACE, major adverse cardiovascular event; NMSC, non-melanoma skin cancer; TB, tuberculosis; VTE, venous thromboembolism.

*Rates shown are n/100 PY=number of patients with at least one event per 100 PY.

A Maximum-Use Trial of Ruxolitinib Cream in Children Aged 2 to <12 Years With Atopic Dermatitis: 8-Week Analysis of Safety, Pharmacokinetics, Efficacy, and Patient-Reported Outcomes

Seth B. Forman, MD,¹ Salma H. Elfaki, MD,² Steve Sitar, MD,³ Shaoceng Wei, PhD,⁴ Xiaohua Gong, PhD,⁴ Brett Angel, MD,⁴ Howard Kallender, PhD,⁴ Mark S. Lee, MD⁵

¹ForCare Clinical Research, Tampa, FL, USA; ²Nona Pediatric Center, Orlando, FL, USA; ³Orange County Research Institute, Anaheim, CA, USA; ⁴Incyte Corporation, Wilmington, DE, USA; ⁵Progressive Clinical Research, San Antonio, TX, USA



Presented at the
32nd European Academy of Dermatology and Venereology (EADV) Congress
Berlin, Germany · 11–14 October 2023

Efficacy

Figure 4. Efficacy improvements were observed at first post-baseline visit (Week 2) and continued to improve to Week 8 in (A) IGA-T3, (B) EASI75, (C) Itch NRS4 (in Patients Aged 6 to <12 Years), and (D) Affected BSA

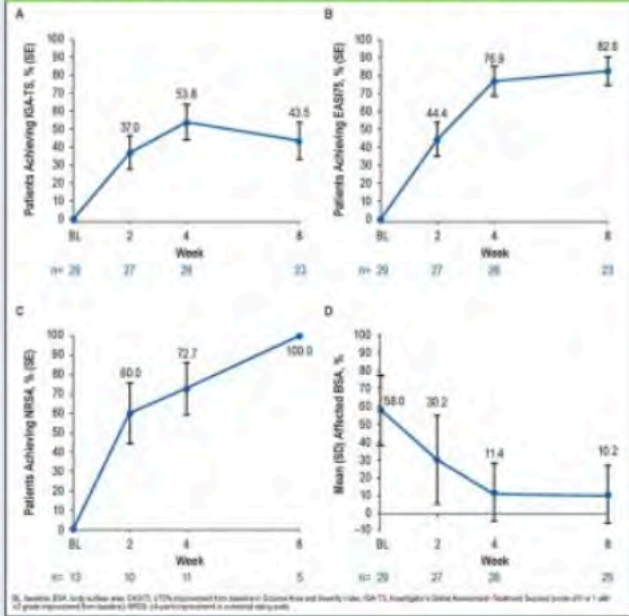
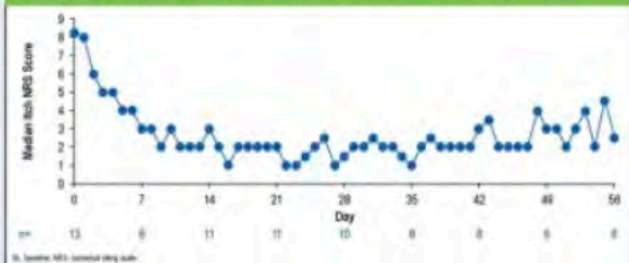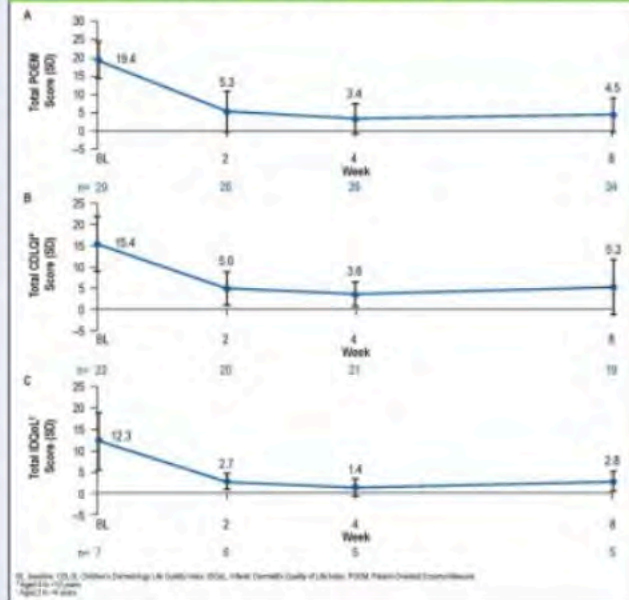


Figure 5. Median Daily Itch NRS Score Among Patients Aged 6 to <12 Years Decreased Early and Was Sustained During the 8-Week Treatment Period, Including With As-Needed Application of Ruxolitinib Cream



PROs

Figure 7. Substantial improvement from baseline in disease severity and quality of life at Week 2, sustained through Week 8: Mean (SD) (A) POEM, (B) CDLQI,⁴ and (C) IDQoL⁴ Scores



Conclusions

- Under maximum-use conditions, 1.5% ruxolitinib cream BID appears to be safe and well tolerated in patients aged 2 to <12 years with moderate or severe AD
- PK, TEAE, and hematologic data suggest that physiologically meaningful systemic JAK inhibition is highly unlikely
 - Consistent with the maximum-use trial in adolescents and adults³
- Ruxolitinib cream had prompt anti-inflammatory and antipruritic effects and improvement in PROs
 - Consistent with previous studies^{2,6}

En niños entre 2 y 12 años buenos resultados en efectividad y seguridad Ruxo tópico 1,5% a las 8 semanas, sin EEAA

- *Treatment of bullous diseases in children*
Prof. Dr. Annika Vogt (Berlin, Germany)



Systematic Review: Emerging Treatment Strategies for Impetigo

- superficial bacterial skin infection, most commonly in children 2 to 5 years of age
- 10 studies that involved 6651 participants and reported on 9 treatments in the final analysis
- rapid emergence and spread of antibiotic-resistant bacteria including MRSA
- increase in antimicrobial resistance to topical mupirocin and fusidic acid

Gahlawat G, Tesfaye W, Bushell M, Abrha S, Peterson GM, Mathew C, Sinnollareddy M, McMillan F, Samarawickrema I, Calma T, Chang AY, Engelman D, Steer A, Thomas J. Emerging Treatment Strategies for Impetigo in Endemic and Nonendemic Settings: A Systematic Review. Clin Ther. 2021 Jun;43(6):986.

Epidemic European Fusidic Acid-Resistant Impetigo Clone (EEFIC)

- Among 518 *S. aureus* strains: 94.0% were susceptible to oxacillin
 of these: 16% were resistant to fusidic acid
 of which: 48% belonged to the EEFIC
- EEFIC: fusidic acid-resistant MSSA clone, harbouring genes encoding the exfoliatins A and/or B
 - Mostly isolated from young patients with impetigo
 - seasonal late summer peak
- 27 of the 50 impetigo-causing strains studied here were FA-R and some were co-resistant to mupirocin

Deplano A, Hallin M, Bustos Sierra N, Michel C, Prevost B, Martiny D, Yin N. Persistence of the Staphylococcus aureus epidemic European fusidic acid-resistant impetigo clone (EEFIC) in Belgium. J Antimicrob Chemother. 2023 Aug 2;78(8):2061-2065.

Considerar
 clindamicina,
 retapamulina,
 Ozenoxacino



Rare: Refractory CBDC

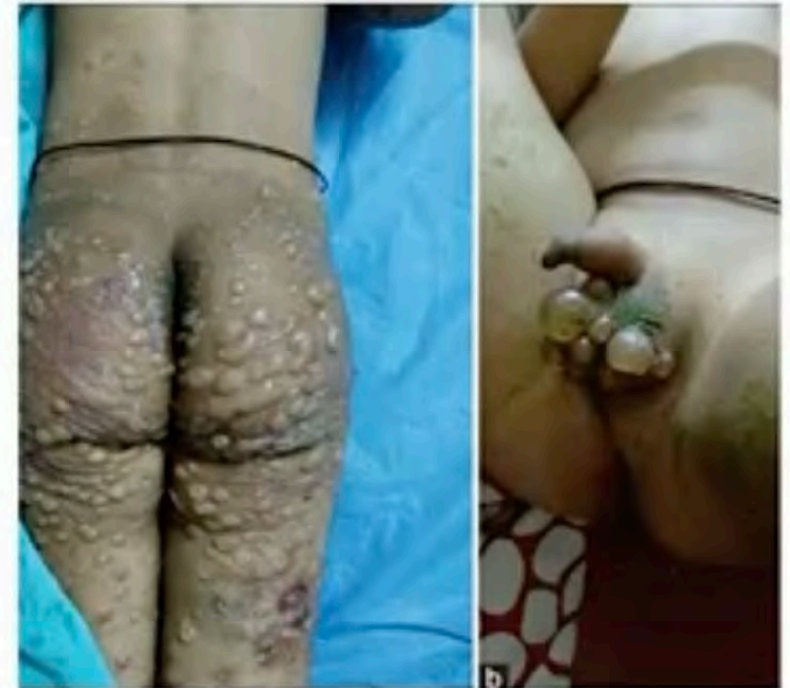2-year-old Child:

History of dapsone hypersensitivity
fever, hypereosinophilia, hepatosplenomegaly, TAs

No therapeutic effects over 6 months

- systemic corticosteroids
- erythromycin, tetracyclin, flucloxacillin
- cyclosporine, methotrexate, azathioprine
nicotinamide, mycophenolate
- IVVG, immunadsorption

Successful treatment with rituximab



Mitra D, Bhatnagar A, Singh GK, Sandhu S. Successful Treatment of Refractory Chronic Bullous Disease of Childhood with Rituximab. Indian Dermatol Online J. 2022 Mar 3;13(2):248-251.



Toxic Epidermolytic Necrolysis

- EN generally considered drug-induced: in children: identification only in approx. 50%
- Numbers vary, letality in children: approx. 6% (lower than in adults)
- Lower incidence in children compred to adults (0,36/Mio <12 years compared to 3/Mio adults)
- Children: Antiepileptics, sulfonamides, sulfasalazin, antibiotics (e.g., amoxicillin (EN vs. DRESS))

Mockenhaupt M. Schwere kutane Arzneimittelreaktionen bei Kindern [Severe cutaneous drug reactions in children]. Monatsschr Kinderheilkd. 2023;171(5):439-451. German..

Systematic review SJS, TEN in children 12 months and younger

Iriarte et al., Pediatr Dermatol. 2022 Nov;39(6):876-882

- Higher affected body surface area correlated with increased mortality
 Mortality numbers vary widely in literature 10-40 %,,: secondary sepsis frequent cause of death
 Optimal therapeutic regimen yet to be established
- Most infants in that cohorte: supportive care only (60%)
 - supportive: 60% survived (n=9)
 - systemic corticosteroids: 60% survived, vs. Immunosuppressive care: both approx. 40% (n=5)
 - IVIG 50% survived (n=2)

**Tratamiento no establecido
 (Falta estudios)**

CTCs, CyA, Ig IV



Bullous Manifestations in the Context of SARS-CoV-2 Infection

03/2020-04/2022 retrospective case series, 6 tertiary medical care centers

Mucobullous conditions:

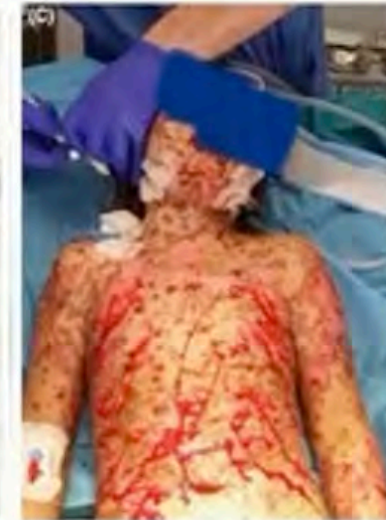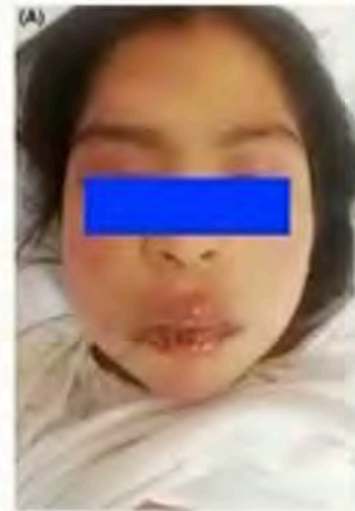RIME, SJS; TEN and positive SARS-CoV-2 test <4 weeks prior to onset

- 86% clinical diagnosis of RIME
- 100 % oral mucosal involvement, 50% ocular, 50% urogenital, 38% skin

Systemic treatment was variable:

- n=6 treated with systemic corticosteroids.
- n=2 elevated MP IgM titers: systemic antibiotics.
- n=1 oral tacrolimus
- n=1 IVIG.

Topical therapies: corticosteroids, hydrogels, and others



Miller AE et al. COVID-19 associated severe mucocutaneous blistering eruptions: A case series. *Pediatr Dermatol.* 2023 Aug 1. doi: 10.1111/pde.15407. Epub ahead of print. PMID: 37526023.

Ryder CY et al. Reactive infectious mucocutaneous eruption secondary to SARS-CoV-2. *JAAD Case Rep.* 2021 Dec;18:103-105.

≠ TEN

Auto-Antibodies in EB

- secondary event, as they appear to not bind to the respective skin structures?

n= 258 EB patients

- autoantibodies in ELISA in 22% of the patients against the bullous pemphigoid antigen BP180.
- titers correlated negatively with collagen VII skin expression and positively with disease severity

n=6 (2.33%) with clinical features of an autoimmune bullous disorder (AIBD)

- and positive indirect immunofluorescence (IIF) staining
- Co-existence disease-aggravating AIBD, young age

Treatment




- Challenging: immunosuppression contra-indicated in JEB and DEB
- risk for development of highly aggressive SCCs
- better understanding of B cell involvement could provide new therapeutic targets.

Pénfigo vulgar neonatal:
tronco y cefálica, raro
acral exclusivo

≠

**Penfigoide gestacional
neonatal:** más frecuente
acral

Px excelente ambas, si
madre clínica típica no
necesario biopsia en niño

EA CONGRESS ADV		Acral blisters in neonates		
Mnif E, Regaieg C*, Sellami K, Khanfir H*, Kolsi N*, Baklouti M, Amouri M, Masmoudi A, Ben Thabet A*, Gargouri A*, Turki H Department of Dermatology, Hedi Chaker Hospital, University of Sfax, Tunisia *Department of Neonatology, Hedi Chaker Hospital, University of Sfax, Tunisia				
Introduction : Neonatal pemphigus (NP) and neonatal bullous pemphigoid (NBP) are rare and transient resulting from the passive transplacental transfer of maternal autoantibodies to fetus. We report 2 cases of NP and a case of NBP with particular clinical presentations.				
	1 st cas	2 nd cas	3 rd cas	
Age	First hour of life	First hour of life	At birth	
Clinical aspect	flaccid fluid-filled blisters and erosions 	flaccid fluid-filled blisters and erosions 	1-Diffuse urticarial plaques 2- Post blistering erosions 	
Localisation	Hands and feet	Hands and feet	1-Tunk, face and limbs 2- Hands and feet	
The mother's medical history	Followed-up for pemphigus	Followed-up for pemphigus	followed-up for gestational pemphigoid.	
Treatment	Local care	Local care	Topical steroids	
Diagnosis	<u>NP</u>	<u>NP</u>	<u>NBP</u>	
Conclusion:				
<ul style="list-style-type: none"> •NP often affects the trunk and the cephalic region. Exclusive involvement of palms and feet is unusual. •NP vulgaris is relatively frequent # NP foliaceus is a very rare entity. It may be a result of desmoglein 3 over expression in neonatal epidermis. •Blisters in NBP, affecting 2 to 3% of newborns of mothers with gestational pemphigoid, can be located in the trunk, limbs and acral areas. •The clinical aspect <u>could wrongly point to an infectious disease</u> hence, the importance of the mother examination and medical history screening. •Biopsy and DIF ; not recommended if the mother has typical lesions. •NP and NBP : good prognosis / usually resolve within the first 3 to 5 weeks of life. •No correlation between the severity of the disease in the baby and the mother. However, stabilization of the disease before conception remains essential. 				



Bullous varicella in an immunocompetent infant

I. Moubine, Fz. El Fatoiki, F. Hali, S. Chiheb

Department of Dermatology and venereology, Ibn Rochd University Hospital



iiDxD!!

Introduction

- **Varicella** is a highly contagious disease caused by the varicella zoster virus (VZV).
- It primarily affects **children** and is mostly **benign**. However, it continues to cause significant **morbidity** and even **mortality**.
- The **bullous onset** of varicella is **rare** and mostly seen in **immunocompromised** children. Herein, we report a case of bullous varicella in an immunocompetent infant.

Observation

- An **8-month-old girl** with no prior medical history or previous drug use
- Admitted to the pediatric department with a history of **fever** and the subsequent **eruption** of **multiple bullous lesions** on the entire body. The lesions started as **vesicles** on the forehead and spread to involve the entire body.
- Her brother had a history of a concomitant varicella infection, which was successfully treated.
- Physical examination revealed **multiple vesicles** and **large erosions**, especially on the trunk, limbs, and face. Nikolsky's sign was negative. (Figs. 1-3)
- A laboratory investigation revealed an increased inflammatory marker. Swab cultures taken from the ruptured bullous were negative. HIV serology was negative, and the immunoglobulin levels were normal.
- The diagnosis of bullous varicella was made based on family history and clinical findings. The patient received intravenous acyclovir for 10 days with good improvement. (Figs. 4,5)

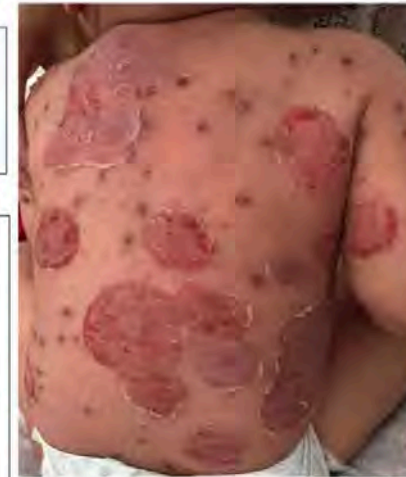

Figure 4

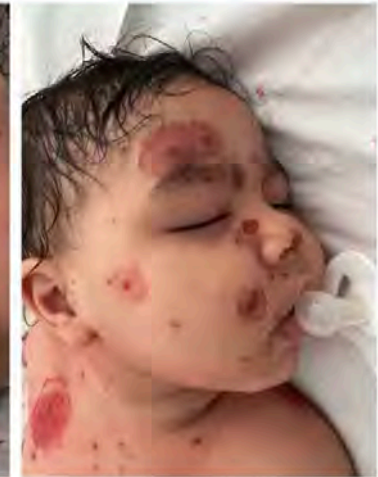

Figure 5

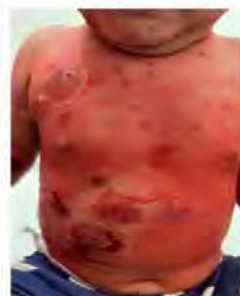

Figure 1

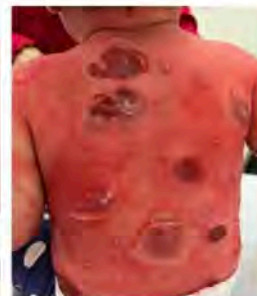

Figure 2

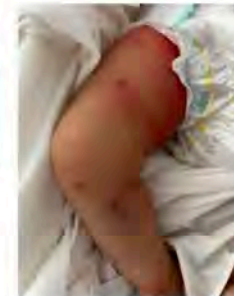

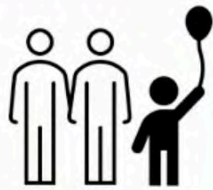Figure 3

Discussion

- Varicella is one of the most common viral infections in children. It may lead to some **complications**, such as **bacterial infections**, **pneumonia**, **meningitis**, **encephalitis**, **cerebellar ataxia**, and **pain syndromes**.
- The most common **cutaneous complication** of varicella is **bacterial surinfection**, which is commonly caused by *Staphylococcus aureus* or *Streptococcus pyogenes* and may worsen scarring and, in rare cases, lead to **staphylococcal** and **streptococcal toxic shock syndromes**.
- **Bullous varicella** is an extremely **rare** clinical manifestation of the disease. The exact mechanisms by which large bullae are formed are not clear; some synergistic effect between the infectious agents must occur. It has been suggested that bullous lesions are caused by secondary **bacterial infections**, most commonly *Staphylococcus aureus*.
- **Vaccination coverage** and **adequate prophylaxis** contribute to avoiding complications in the **high-risk population**.

Melanoma in congenital melanocytic naevi
Prof. Dr. Cristina Carrera (Barcelona, Spain)

Pediatric melanomas in CMN:



Associated GCMN

100% congenital nevus associated

Childhood or any age!!

Giant / Multiple CMN

No UVR relation

NRAS mutations

Conventional MM

80% nevus associated
 (any type of nevus)

Adolescents and adults

Nevus-prone and fair-skin

Intermittent UVR pathway
 (similar to adults)

BRAF mutations (V600)

Spitz MM

NO nevus related

Childhood and AYA

No risk-phenotype

No UVR relation

HRAS / Kinase fusions

Lu et al. *J Invest Derm* 2015; 135:816-823

Pappo et al. *Cancer* 2021;127:3825-3831

- Generalmente, **adolescentes**
- **Tres FR aceptados de MM en NMC:**
 - Gigantes
 - Múltiples pequeños/medianos
 - Alteraciones NRL en primeros 6 meses de vida
- En general, no necesario excisión
- Se **realizan muchas más exéresis de las necesarias**

PAEDIATRIC DERMATOLOGY

2012 167, pp368–373

BJD
 British Journal of Dermatology

Excised melanocytic lesions in children and adolescents – a 10-year survey

E. Moscarella,¹ I. Zalaudek,² L. Cerroni,² I. Sperduti,³ C. Catricalà,¹ J. Smolle,² R. Hofmann-Wellenhof,² A. Sgambato,⁴ G. Pellacani⁵ and G. Argenziano⁶

NNE in pediatric population: 594 nevi: 1 MM

0-4y: no MM
5-9y: no MM
10-14y: 5 MM (NNE: 1140 Nevi: 1 MM)
15-19y: 33 MM (NNE: 480 Nevi: 1 MM)

NNB 1035: 1 MM (2009-2013 in US)**

** Oliveria et al. JAMA Dermatol 2015

- > mutación nRAS
- Pronóstico de MM sobre NMC: malo.

Multiple Congenital Melanocytic Nevi and Neurocutaneous Melanosis Are Caused by Postzygotic Mutations in Codon 61 of *NRAS*

Verónica A. Kirsler^{1,2}, Anna C. Thomas¹, Mihai Ishida³, Neil W. Bulstrode¹, Sam Loughlin⁴, Sandra Hing¹, Iger Palmer¹
Journal of Pediatric and Developmental Pathology 18, 1-9, 2015
 DOI: 10.23907/18101960QA1
 © 2015 Society for Pediatric Pathology

BRAF Mutations Are Also Associated with Neurocutaneous Melanocytosis and Large/ Giant Congenital Melanocytic Nevi

CLÁUDIA M. SALGADO,¹ DIPANKAR BASU,¹ MARINA NIKIFOROVA,² BRUCE S. BRAUER,³ DONALD JOHNSON,³ VERÓNICA RINDELL,² LORELEI J. GRUNWALD,⁴ AND MIGUEL REYES-MUGICA^{1*}

Genetic Abnormalities in Large to Giant Congenital Nevi: Beyond *NRAS* Mutations

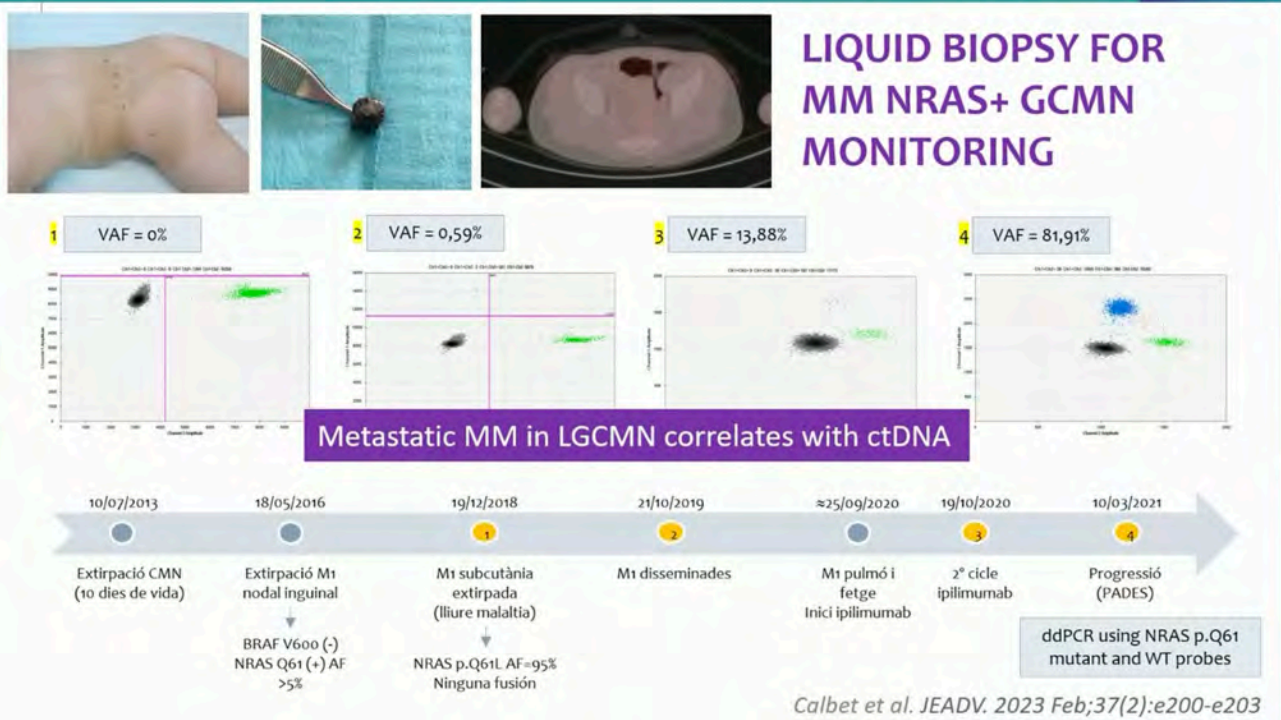
Vanessa Martins da Silva¹, Estefania Martinez-Barrrios², Gemma Tell-Martí^{1,3}, Marc Dabad^{3,4}, Cristina Carrera^{1,3}, Paula Aguilera^{1,3}, Daniel Brualla⁵, Anna Esteve-Codina^{4,5}, Asunción Vicente⁶, Susana Puig^{1,3}, Joan Anton Puig-Butillé^{2,3,7,8} and Josep Malvehy^{1,2,8}

doi:10.1016/j.jid.2018.07.045

Molecular drivers

NRAS 68%
BRAF 7%
MET, GNAQ, ... fusion transcripts
No relation to the risk:

- Neurocutaneous syndrome
- Melanoma development



- Problema: **nódulos sobre NMC**
- Dificultad también en la biopsia
- Necesidad estudio NGS sobre biopsia
- **Estudio BL: ayuda en la monitorización nRAS**

Nodular lesions on giant congenital nevus: the role of molecular analysis with SNP-array.

Bordin C.¹, Tolone M.², Diociaiuti A.³, Gisondi P.¹, Girolomoni G.¹, El Hachem M.³

¹Section of Dermatology and Venereology, Department of Medicine, University of Verona, Verona.

²Department of Health Sciences, Magna Graecia University, Catanzaro.

³Dermatology Unit and Genodermatoses Research Unit, Bambino Gesù Children's Hospital, IRCSS, Rome.

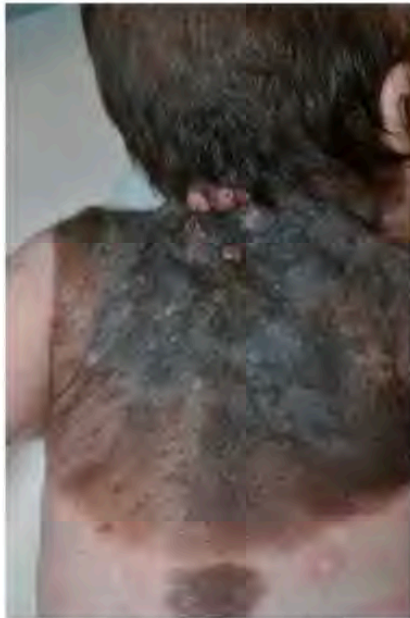

Figure1: patient at the age of 1 year.

Introduction & Objectives: We present the case of a 4-year-old patient affected by giant congenital melanocytic nevus (GCMN) of the back, extending to the head and left mandibular region with numerous satellite lesions of various sizes on the limbs, abdomen and face. MRI of the brain and spinal cord performed at one month of age was negative for neuromelanosis and the ophthalmological examination was normal. During her first years of life, she developed two nodular lesions arising from the GCMN: at the age of two months, a polypoid ulcerated nodule appeared in the nuchal region and at the age of 3 years the patient developed a new greyish nodular lesion on the dorsal interscapular region.

Materials & Methods: The patient underwent regular clinical and dermoscopic examination and every nodular lesion was biopsied. Both nodules were analysed through histopathological, histochemical and molecular examination (SNP-array).

Results: For the differential diagnosis between proliferative nodule and malignant lesion, histological examination and immunohistochemistry were performed. In both cases they were suggestive, but not decisive for melanoma. Therefore, molecular diagnosis with SNP-array was performed.

In the first lesion monosomies of various chromosomes and trisomy of chromosome 22 were highlighted, while no segmental chromosomal alterations were detected. The diagnosis was a proliferative nodule. Although the lesion was classified as benign, in consideration of the morphological aspects, a strict clinical and ultrasound follow-up was planned.

Regarding the second lesion, SNP-array showed multiple chromosomal imbalances, both aneuploidies and segmental alterations, in particular in the loci 8q.24 (MYC gain) and 1q (gain), which are

When faced to a congenital mass protruding from vagina, think of botryoid rhabdomyosarcoma

B.BENNOUR, S.ABDEL-ILAH, M.ABOUDOURIB, S.AMAL, O.HOCAR
Dermatology department- Arrazi hospital - Biosciences laboratory
Mohamed VI university hospital Marrakech Morocco

iiDxD!!

Introduction

Gynaecologic neoplasms are rare in children. Rhabdomyosarcoma (RMS) are malignant mesenchymal tumors deriving from myogenic progenitor that represents one of the most common soft tissue sarcomas of childhood.

It is often found in the genital tract of infants and young children and may be exceptionally congenital. We report a rare case of a congenital botryoid RMS.

Case report

A female newborn presented 3 congenital papillomatous tumors in the vulvar area with vaginal and anal extension.

The histological study revealed spindle cells proliferation with high cellularity, the epidermis was hyperplastic and pseudo-sarcomatous. Immunohistochemistry showed a moderate expression of desmin, myogenin and Ki67 markers. Protein S100 was negative. The diagnosis of congenital botryoid rhabdomyosarcoma was retained.

The therapeutic management was to put the patient under chemotherapy according to the VAC protocol and to perform a tumor resection after regression of the lesions in order to avoid the anatomical damage of the ano-vulvar region.

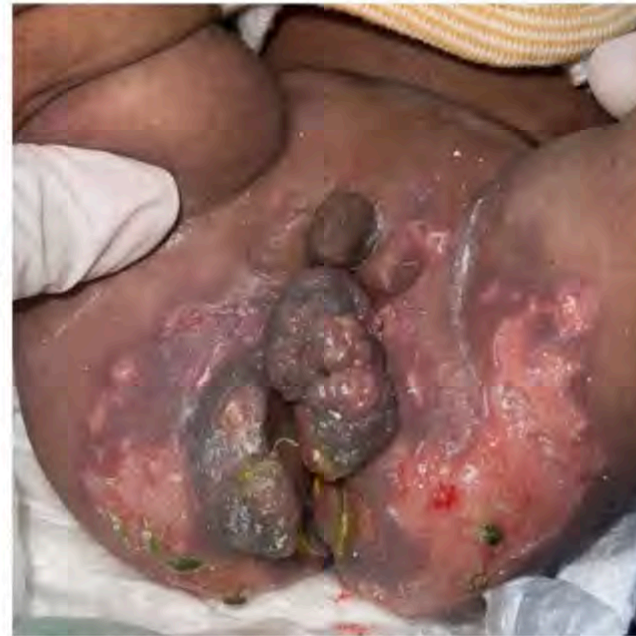

Figure: Congenital botryoid rhabdomyosarcoma

in which vulvar location and congenital onset were associated (1).

Four major histologic subtypes of RMS are identified: embryonal, alveolar, pleomorphic, and sclerosing/spindle cell(2). Embryonal RMS (ERMS) is the most common type of all RMSs frequently arising in the pediatric female genitourinary tract(3). A study on 67 female children with ERMS showed that uterine RMSs were most often seen during adolescence however, vagina was the primary site in 68.4% of children between 0 and 9 years.(4)

Botryoid variant is a type of ERMS often occurring frequently in the vagina, characterized by 'grape-like' appearance caused by polypoid mass arising in submucosal tissue(5). Histological findings helps eliminate sacrococcygeal teratoma neuroblastoma and Burkitt's lymphoma. Recently, authors have highlighted a variety of genitourinary ERMS associated with a somatic or a germline DICER1 mutation(6)(7). The combination of surgery and chemotherapy (Vincristine, dactinomycin, and cyclophosphamide) with or without radiotherapy or brachytherapy provides good results in early stage of genital ERMS(8)

Primary cutaneous CD4+ small/medium T-cell lymphoproliferative disorder in children: a cases series of fourteen patients

Seguí M¹, Olivares-Guerrero M¹, Noguera-Morel L², Hernández-Martín A², Colmenero I³, Campos-Domínguez M⁴, Kempf W⁵, Gru A⁶, Torrelo-Fernández A², Llamas-Velasco M¹.

¹Department of Dermatology, Hospital Universitario de La Princesa, Madrid, Spain, ²Department of Dermatology, Hospital Infantil Universitario Niño Jesús, Madrid, Spain, ³Department of Pathology, Hospital Infantil Universitario Niño Jesús, Madrid, Spain, ⁴Department of Dermatology, Hospital General Universitario Gregorio Marañón, Spain, ⁵Department of Dermatology, University Hospital Zurich, Zurich, Switzerland, ⁶Department of Pathology, University of Virginia School of Medicine, Charlottesville, Virginia, USA

Results: Fourteen patients were included, nine males and five females, aged between 1 and 16 years old. All patients presented as a single lesion and the most frequent location was the head. The histological findings were similar to those described in adults, with lymphoid proliferation in the papillary and reticular dermis composed of polymorphic lymphoid cells, recognizing small and medium-sized lymphocytes. The immunohistochemical study revealed a T phenotype (CD3+, CD4+, CD8-). The molecular study was positive for the monoclonal rearrangement of TCR gamma. All patients presented an indolent course with resolution after surgical treatment. In two cases, spontaneous regression was demonstrated after an incisional biopsy. In none of the cases recurrence was observed during follow-up of 38 months (2-55 months).

Conclusions: We present the largest case series of PCSM-LPD described in the literature in the paediatric age. As in adult populations, paediatric PCSM-LPD appears to most commonly present as a single lesion on the head or neck and have an excellent clinical prognosis, and thus further staging cannot be recommended. Surgical excision is the preferred mode of treatment, although spontaneous regression after biopsy has been described, therefore observation may be an option in these patients.

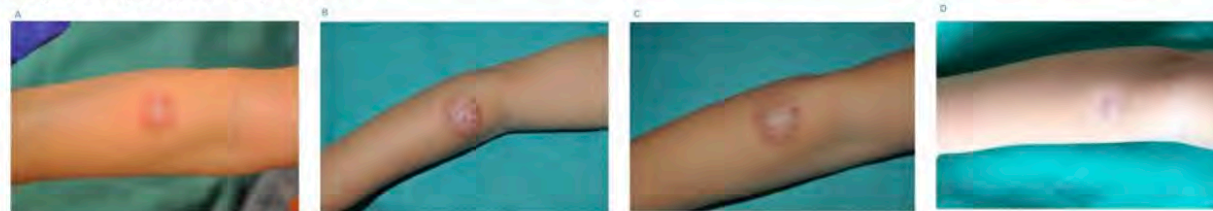


Figure 1. Clinical images. A) Initial clinical presentation of one of the patients: erythematous nodule on the forearm. B) 1 month after the biopsy: increase in the size of the lesion with a scar at the center and telangiectasias at the periphery. C) Two months after the biopsy: the lesion experienced spontaneous regression D) Six months after the biopsy: complete regression with a residual hypopigmented macule.

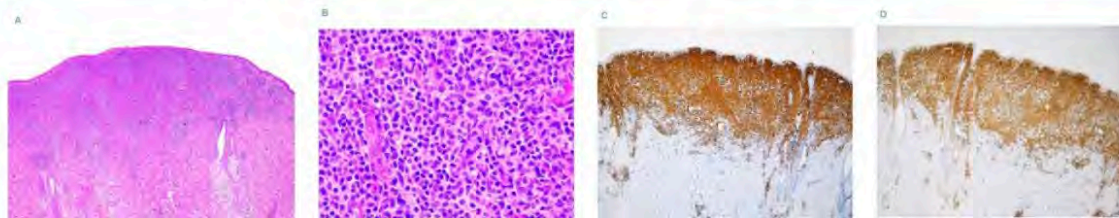
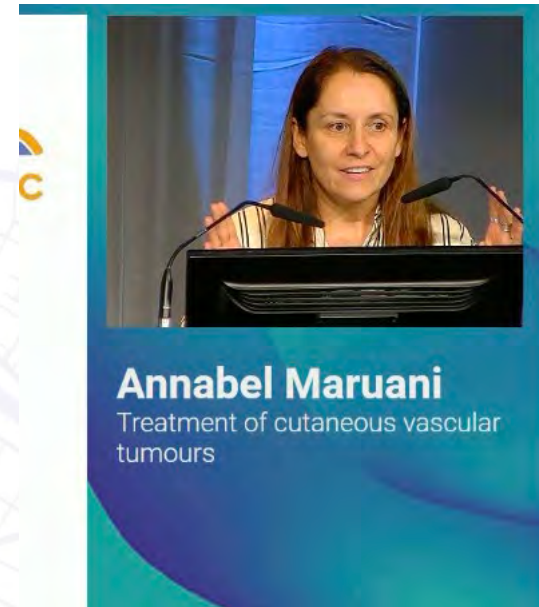

Figure 2. Biopsy specimens. A) At low magnification, a lymphoid proliferation is identified that diffusely occupies the papillary and reticular dermis. B) At high magnification, these small and medium-sized lymphocytes are recognized, which are pleomorphic, with elongated nuclei and a large, poorly defined cytoplasm. C) With immunohistochemistry techniques, lymphoid cells diffusely express CD3. D) As well as CD4. E) As well as CD4.)

**Serie + larga de
TCD4+ CP/M,
español, muy
recomendable**

Treatment of cutaneous vascular tumours

16:20 - 16:40 CEST



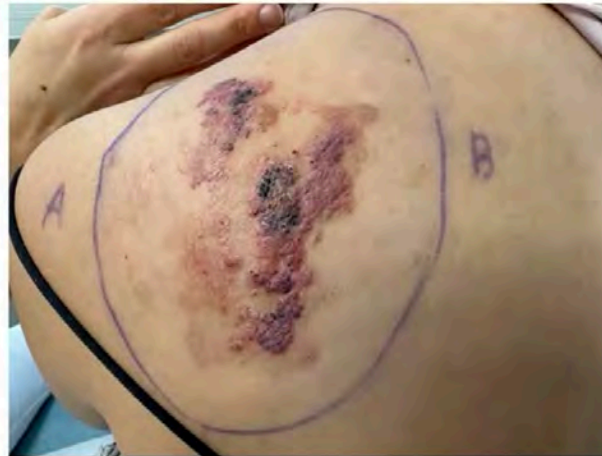- **Sirolimus oral:**

- Mejoría **linfática** > **venosa**

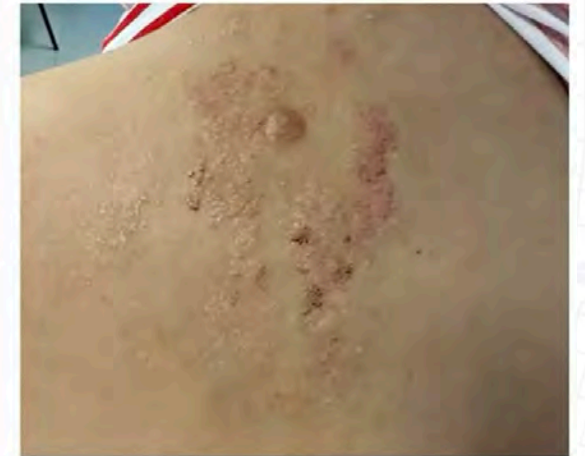Sirólimus tóxico:

Malf linfática microquística

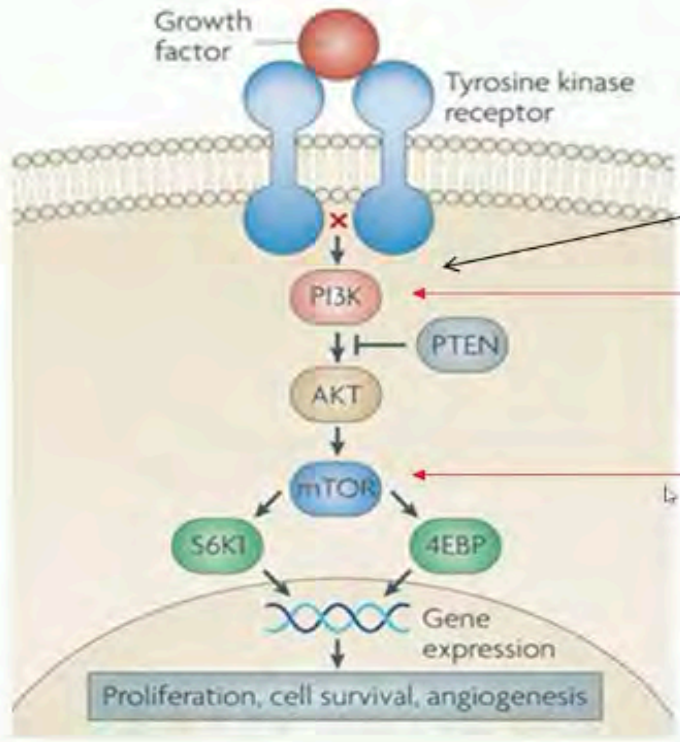
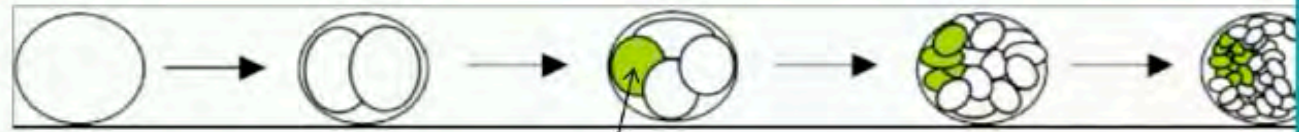
Topical sirolimus (rapamycin) 0.1% cream 1/day



→
6 months



Post-zygotic gene mutations



Mutations of PIK3CA

PI3K inhibitors
(alpelisib)

mTOR inhibitors
(sirolimus)

Nature 2018

ARTICLE

<https://doi.org/10.1038/s41586-018-0217-9>

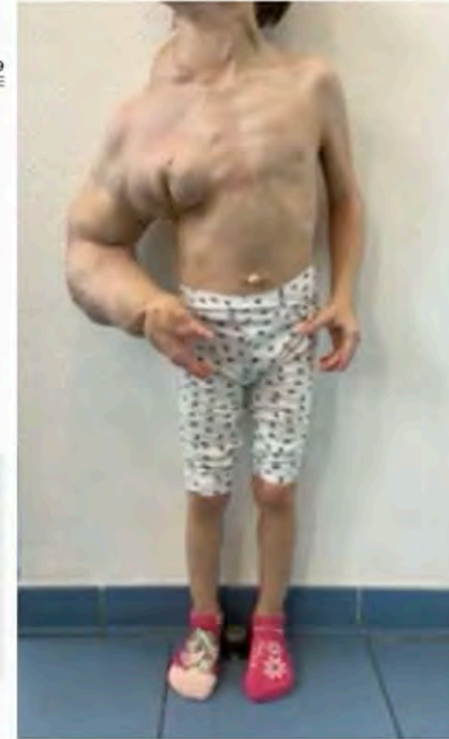
Targeted therapy in patients with PIK3CA-related overgrowth syndrome

Quitterie Venot¹, Thomas Blanc^{1,2,3,21}, Smail Hadj Rabia^{2,4,5,21}, Laureline Berteloot^{5,6}, Sophia Ladraa¹, Jean-Paul Duong^{2,7}, Estelle Blanc⁸, Simon C. Johnson⁹, Clément Huguin¹, Olivia Boccarda⁴, Sabine Sarnacki^{2,3}, Nathalie Boddaert^{2,5,6}, Stephanie Pannier^{2,10}, Frank Martinez¹¹, Sato Magassa¹, Junna Yamaguchi¹, Bertrand Knebelmann^{1,2,11}, Pierre Merville^{12,13}, Nicolas Grenier¹⁴, Dominique Joly^{1,2,11}, Valérie Cormier-Daire^{2,5,15}, Caroline Michot^{2,5,15}, Christine Bole-Feysot², Arnaud Picard^{2,16}, Véronique Soupre¹⁶, Stanislas Lyonnet^{2,5,15}, Jeremy Sadoine¹⁷, Lotfi Slimani¹⁷, Catherine Chaussain^{2,17}, Cécile Laroche-Raynaud¹⁸, Laurent Guibaud¹⁹, Christine Broissand²⁰, Jeanne Amiel^{2,5,15}, Christophe Legendre^{1,2,11}, Fabiola Terzi^{1,2} & Guillaume Canaud^{1,2,11*}

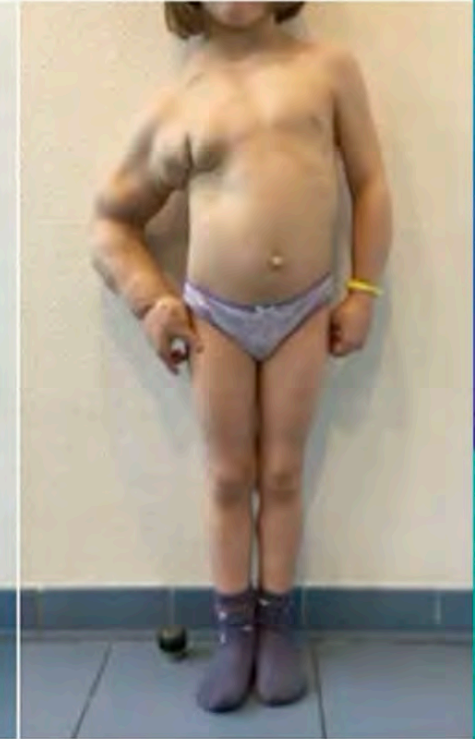CLOVES syndrome (congenital lipomatous overgrowth, vascular malformations, epidermal naevi, scoliosis/ skeletal and spinal syndrome) is a genetic disorder that results from somatic, mosaic gain-of-function mutations of the *PIK3CA* gene, and belongs to the spectrum of *PIK3CA*-related overgrowth syndromes (PROS). This rare condition has no specific treatment and a poor survival rate. Here, we describe a postnatal mouse model of PROS/CLOVES that partially recapitulates the human disease, and demonstrate the efficacy of BYL719, an inhibitor of *PIK3CA*, in preventing and improving organ dysfunction. On the basis of these results, we used BYL719 to treat nineteen patients with PROS. The drug improved the disease symptoms in all patients. Previously intractable vascular tumours became smaller, congestive heart failure was improved, hemihypertrophy was reduced, and scoliosis was attenuated. The treatment was not associated with any substantial side effects. In conclusion, this study provides the first direct evidence supporting *PIK3CA* inhibition as a promising therapeutic strategy in patients with PROS.

Randomized controlled trials are ongoing

Day 0



Day 180





Alpelisib for a PIK3CA- Related Vascular Anomaly

Yaron Gu^{1,2}, Simon King³, Deshan Frank Sebaratnam^{1,2}

¹South West Sydney Clinical Campuses, University of New South Wales, Liverpool, NSW 2170, Australia

²Department of Dermatology, Liverpool Hospital, Liverpool, NSW 2170, Australia

³Department of Anatomical Pathology, Pathology North, John Hunter Hospital, Newcastle, NSW, Australia

CASE REPORT

A 25-year-old female presented for review of a vascular birthmark. She reported increasing pain, bleeding, and soft tissue overgrowth within a congenital plaque on her right flank. She reported temporary symptomatic relief with cauterly and debulking surgery performed years prior to presentation. Her past medical history was remarkable for cross-fused renal ectopia and endometriosis. The birthmark caused significant pain for which she had previously trialled multiple analgesics with minimal improvement. Examination revealed a geometric maroon patch measuring 35cm by 30cm. It was studded with dark vesicles, characteristic of microcystic lymphatic malformations in association with soft tissue swelling (Fig 1a).

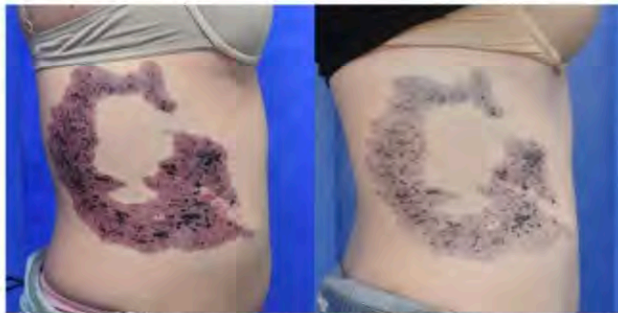


Figure 1: PIK3CA-related vascular anomaly composed of capillary, lymphatic and venous malformations (a) at presentation and (b) two months follow up

Incisional biopsy demonstrated dilated, thin-walled vessels

Her presentation was in keeping with a PIK3CA-related vascular anomaly composed of capillary, lymphatic and venous malformations. Given the morbidity associated with her birthmark, she was commenced on targeted treatment with a PI3K inhibitor, alpelisib 250mg once daily. At two-month follow-up, there was significant improvement with lightening of the capillary malformation and decrease in the number of microcystic lymphatic malformations (Fig 1b). Repeat MRI demonstrated reduced vascular calibre in the right flank with reduction in the tributaries of her lesion (Fig 2b). The patient no longer had associated pain with her lesion.

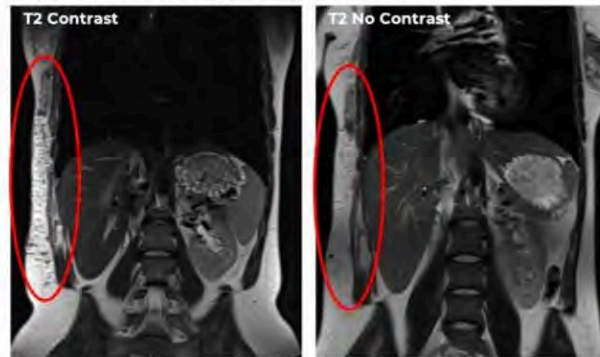

Figure 2: MRI findings at (a) presentation and (b) four month follow up demonstrating reduction in vascular calibre and tributaries of the lesion

DISCUSSION

The PIK3CA-associated vascular anomalies are a subset of PIK3CA-related vascular anomalies.

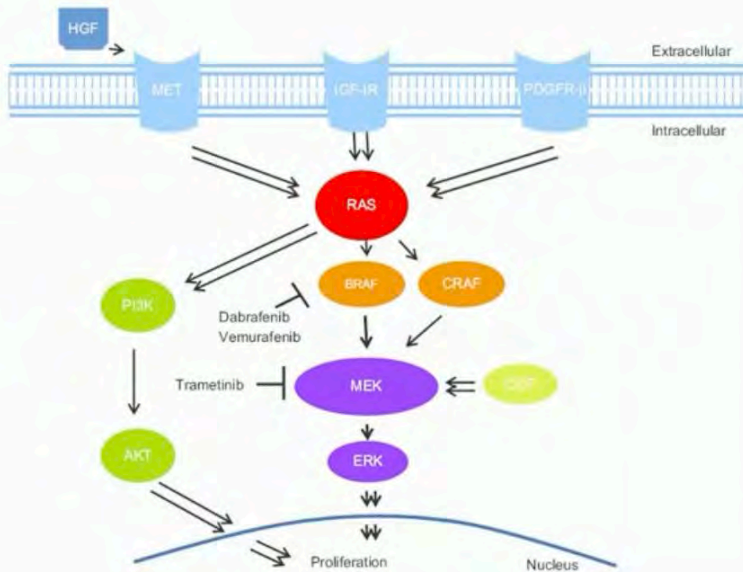
Alpelisib effects landmark overgrowth patient demonstrates recent of alpe

In Australia approved PIK3CA compound disorder one of the clinical and ge

1. Canavac mechar manifes doi:10.1
2. Venot (related doi:10.1
3. Garrett CLOVES

Futuro de
PROS:
Alpelisib
Hiperglucemia

Somatic mutations identified in extracranial arteriovenous malformations



- Pathogenic variants in 78.3% of cases (n=18/23) :

MAP2K1 (Mitogen-activated protein kinase kinase 1) (n=7), KRAS (n=6), RASA1 (n=3), BRAF (n=2)

El Sissy FN, et al. JEADV 2022

- Activation of the RAS/MAPK signaling pathway: a place for anti-MEK drugs (trametinib)?

Kainthla R. Pharmacogenomics and Personalized Medicine. 2013

Lekwuttikam R, et al. JAMA Dermatol. 2019

Edwards EA, et al. Pediatrics. sept 2020

*Prospective studies are ongoing
(trametinib and cobimetinib, NCT05125471)*

P0337 Successful Treatment of Angiolymphoid Hyperplasia with Eosinophilia by Propranolol

Kaoutar Elmachichi, Maryem Aboudouraib, Ouafa Hocar ,Said Amal

Mohammed VI University Hospital of Marrakech , Department of Dermatology, Marrakech, Morocco

Introduction

Angiolymphoid hyperplasia with eosinophilia (ALHE) is a rare idiopathic condition, usually seen in adults and characterized by the presence of isolated or grouped papules, plaques or nodules in the skin of the head and neck region, specifically on the preauricular region. In the view of management, majority of related reports of therapeutic methods comprise of surgical excision, intralesional/topical/systemic corticosteroid...

In some cases, the oral propranolol was demonstrated as an alternative treatment of ALHE. Here we reported a case of a 30-year-old woman with ALHE successfully treated with propranolol.

Case report

A 30-year-old woman, without past medical history was admitted with multiple painful papules, appeared 7 months ago, spontaneous bleeding in the auricle and the preauricular area

Physical examination revealed multiple red-brown firm dome-shape papules in the helix and antihelix, without any other cutaneous lesions. There was no local or regional lymphadenopathy, and other system examination were unremarkable and the complete blood count was normal.

Surgical removal of one of the lesions was performed and pathological examination confirmed the histological diagnosis of ALHE.

The patient was started on oral propranolol 40 mg once daily. Within 2 months, several of the lesions had decreased. Propranolol was subsequently stopped within 8 months of initiating treatment after a complete disappearance of all lesions and without any adverse effects of the medication (Fig 1,2,3).

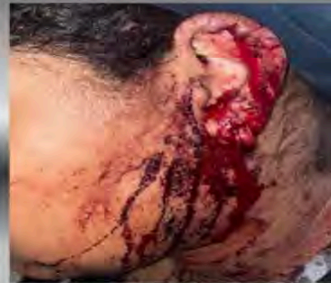

Fig 1: Violaceous papules with a spontaneous bleeding.

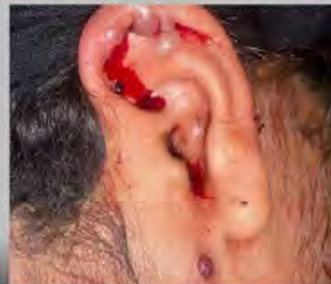

Fig 2: Regression of the bleeding after two months of treatment.

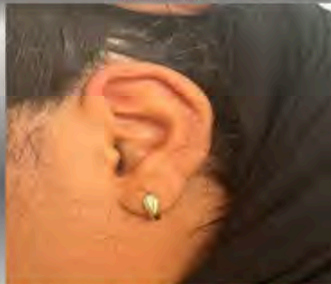


Fig 3 disappearance of all lesions after 8 months of treatment.

Discussion

Angiolymphoid hyperplasia with eosinophilia is a benign, locally proliferating disease but the pathogenesis is not clearly understood whether it consists of a vascular neoplasm or a lymphoproliferative process.

ALHE commonly present with some symptoms, like pruritus, spontaneous bleeding and pain. This is consistent with our patient that had intense pain and bleeding. It tends to arise in the skin of the head and neck, particularly in the scalp and the periauricular area. Other features include regional lymphadenopathy and peripheral eosinophilia which is an inconstant feature as in our case.

Histologically, it is characterized by proliferation of vascular channels with inflammatory infiltrate composed of lymphocytes and eosinophils.

However, from previous case reports, surgical excision is considered as the most effective. Moreover, some reported cases showed the interesting successful treatment by oral propranolol. Although the definite mechanism remains unclear, the hypothesis has been proposed that beta-blocker-induced localized vasoconstriction, inhibition of angiogenesis and apoptosis of capillary endothelial cells.

Our case, shows that oral propranolol is one of the good therapeutic options in the treatment of ALHE with an excellent improvement in clinical presentations and symptoms and without any adverse effect.

References

- 1- Horst, C.; Kapur, N. Propranolol: a novel treatment for angiolymphoid hyperplasia with eosinophilia. Clin Exp Dermatol. 2014 Oct;39(7):810-2.
- 2- Guo, Ruifeng; Gavino, Alde Carlo P. Angiolymphoid Hyperplasia With Eosinophilia. Arch Pathol Lab Med. 2015 May;139(5):683-6
- 3- Bahloul E; Ben Rejeb; Khaoula B; Ons B, et al. Successful treatment of angiolymphoid hyperplasia with eosinophilia with oral propranolol in two cases . Dermatol Ther 2021 Jul;34(4):e14994
- 4- Allyson B, Brigitte S, Heidi M et al. Angiolymphoid Hyperplasia with Eosinophilia: Many Syllables, Many Unanswered Questions. J Clin Aesthet Dermatol. 2021 Jun;14(6):49-54.

Eficacia de Propranolol en hipreplasia angiolinfoide con eosinofilia



- **Fármacos biológicos en psoriasis:** 1ª línea, probablemente IL17 mejor que TNF. Nuevas moléculas en estudio.
- **Fúngicas:** siempre tenerlas presentes, tratamiento temprano evitar alopecia permanente. Griseofulvina/Terbinafina. Tratamiento convivientes.
- **DA infantil:** revolución biológica y de pequeña molécula → indicaciones, posología. ¿Posibilidad de detener o curar la marcha/Espectro atópico?
- **Ampollosas:** +F infecciosas, cuidado enfs graves (toxicodermias, AI, etc.). Post-virales simulan TEN. Ac en EB
- **Melanoma en NMC:** gigantes, satélite, alteración en SNC / 2º subgrupo: ≈ a población general, típico adolescentes mayores
- Tratamiento de **tumores vasculares cutáneos:** importancia sirólimus / alpelisib / y otras que vendrán tto dirigido

Gracias



AEDV2023
Highlights



Miguel Mansilla Polo

Hospital Universitario y Politécnico La Fe



@mig_vec



La Academia Española de Dermatología y Venereología expresa su agradecimiento al patrocinador UCB, por su especial apoyo y contribución con la actividad formativa Highlights 2023.



AEDV
Highlights
2023



32º EDICIÓN • 32º EDICIÓN • 32º EDICIÓN • 32º EDICIÓN • 32º EDICIÓN • 32º EDICIÓN • 32º EDICIÓN • 32º EDICIÓN • 32º EDICIÓN • 32º EDICIÓN

**BER
LIN**

11-14 OCTUBRE

AEDV 2023 Highlights



32º EDICIÓN • 32º EDICIÓN • 32º EDICIÓN • 32º EDICIÓN • 32º EDICIÓN • 32º EDICIÓN • 32º EDICIÓN • 32º EDICIÓN • 32º EDICIÓN • 32º EDICIÓN

BER LIN

11-14 OCTUBRE

Con el patrocinio de:



Iniciativa científica de:

